

Case Based Learning Program

**The Department of Urology
Glickman Urological & Kidney Institute
Cleveland Clinic**

Case Number 5

Case Based Urology Learning Program

Editor:	Steven C. Campbell, MD PhD Cleveland Clinic
Associate Editor:	Jonathan Ross, MD Rainbow Babies & Children's Hospital, UH
Manager:	Nikki G. Williams Cleveland Clinic
Case Contributor:	Steven C. Campbell, MD PhD Cleveland Clinic



Cleveland Clinic

Glickman Urological and Kidney Institute



Rainbow Babies
& Children's Hospital



University Hospitals
Case Medical Center

A 36-year-old female is found to have bilateral solid, enhancing renal masses.

CT scan shows an 8 cm hilar mass on the R side with a renal vein thrombus, and a 2.2 cm exophytic, polar lesion on the left.

Metastatic evaluation is negative. The SCr level is 0.8 mg/dl (eGFR > 60 ml/min/1.73 m²).

The patient has a history of hysterectomy at age 28.

What other history is particularly relevant?

What other history is particularly relevant?

A family history is highly relevant in any patient with early onset, multifocal renal tumors. This should detail any personal or family history of kidney tumors, eye tumors, CNS tumors, blindness, kidney failure, or any other manifestations of the familial RCC syndromes.

What is the differential diagnosis?

What is the differential diagnosis?

Bilateral RCC at this age can be sporadic but familial etiology must be considered. The differential diagnosis thus should include VHL syndrome, hereditary papillary RCC, hereditary leiomyomatosis RCC, Birt-Hogg Dube, familial oncocytoma syndrome, and tuberous sclerosis.

What is the most likely diagnosis?

What is the most likely diagnosis?

Hereditary leiomyomatosis RCC is often associated with early onset, multifocal RCC, leiomyomas of the skin or uterus, and uterine leiomyosarcoma. Many women with this syndrome have a history of hysterectomy at a very early age, as in this case.

What gene is mutated in this syndrome?

What gene is mutated in this syndrome?

Fumarate hydratase (1q42-43), an enzyme in the Krebs cycle. This mutation inactivates the Krebs cycle which is critically important to aerobic metabolism. This forces the cell to depend primarily on anaerobic metabolism. This in turn stimulates maladaptive responses, such as hypoxia driven pathways, and increased angiogenesis. This is just one example of the common relationship between metabolic pathways and RCC.

Is this an oncogene or a tumor suppressor gene and what is the pattern of inheritance?

Is this an oncogene or a tumor suppressor gene and what is the pattern of inheritance?

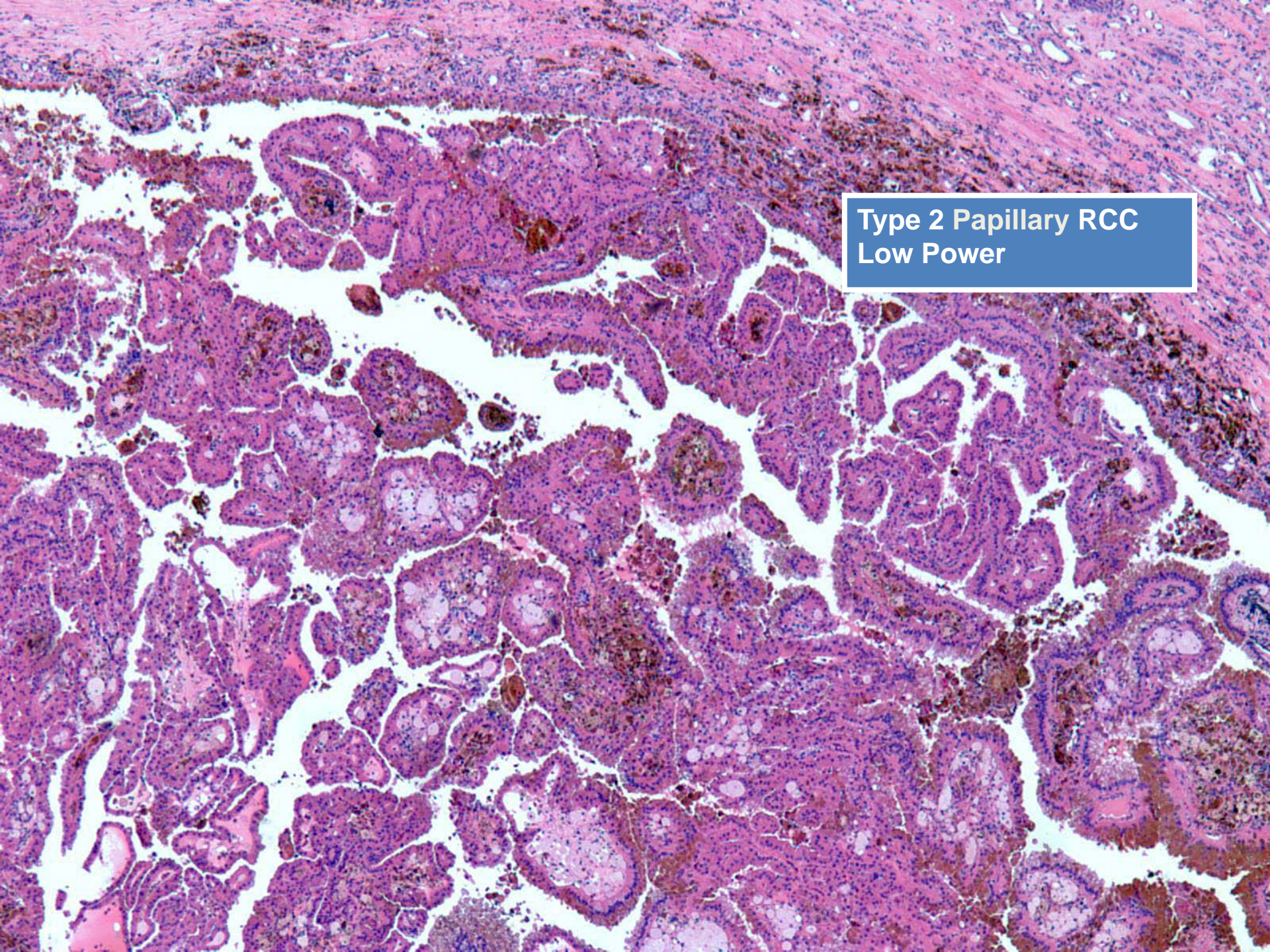
This is a tumor suppressor gene. The c-Met gene that is responsible for hereditary papillary RCC is an oncogene. All other genes that cause hereditary RCC are tumor suppressor genes. All hereditary RCC syndromes, without exception, are inherited in an autosomal dominant manner.

What is the likely pathology of the renal tumors?

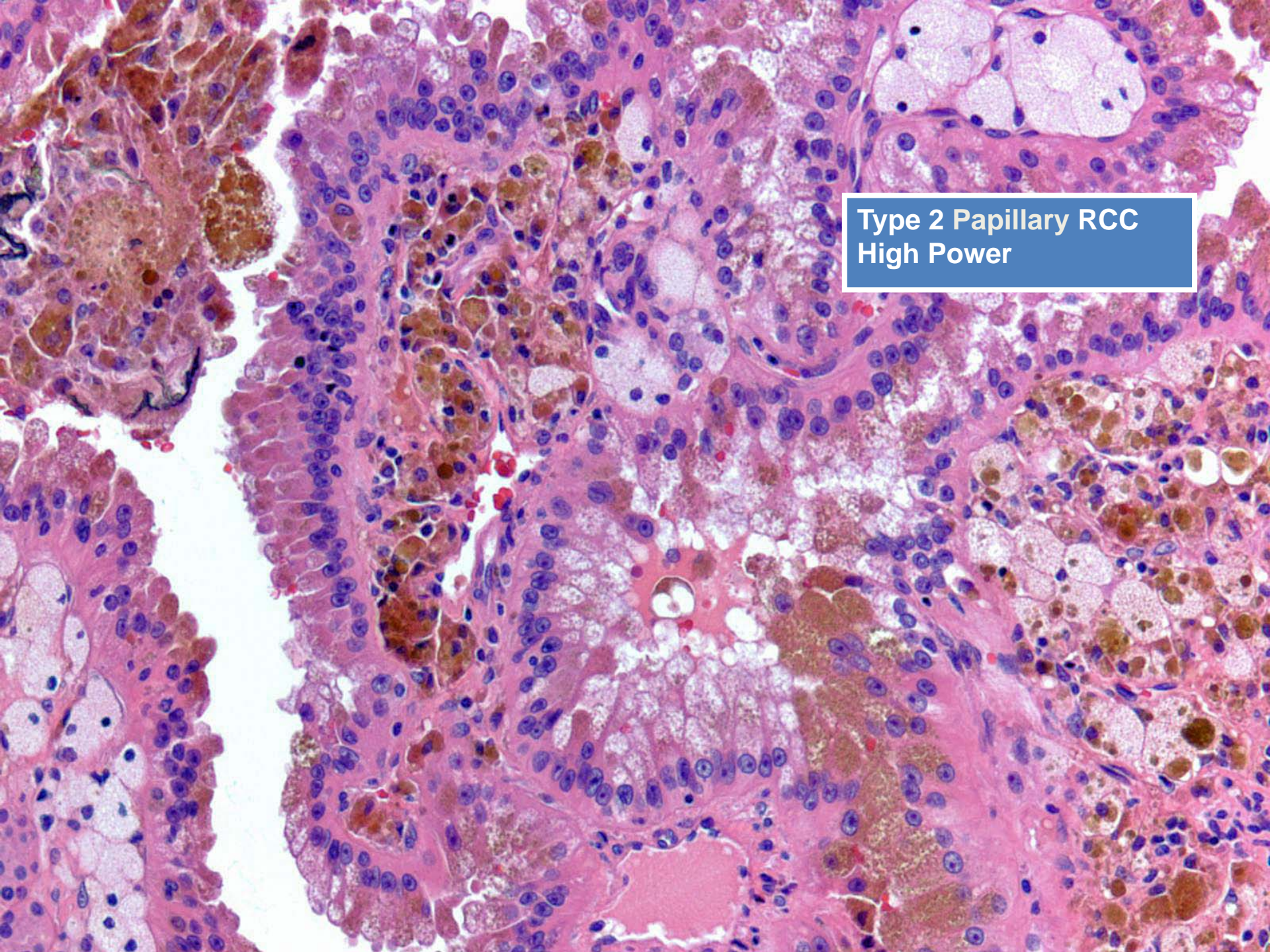
What is the likely pathology of the renal tumors?

Type 2 papillary RCC

Type 2 Papillary RCC
Low Power



Type 2 Papillary RCC
High Power



How should the patient be managed?

How should the patient be managed?

A right radical nephrectomy should be considered first because this lesion is locally advanced. Type 2 papillary RCC tends to be aggressive, which is unique for the familial RCC syndromes. It must be managed aggressively. The “3 cm rule” that applies to most familial tumors may not be appropriate for this syndrome. For other familial syndromes of RCC the 2.2 cm contralateral lesion would be observed until it reaches the 3 cm threshold, but tumors in familial leiomyomatosis should in general be managed more aggressively. Hence a L partial nephrectomy should also be considered, either as a staged procedure or simultaneous with the contralateral radical nephrectomy.

Selected Reading

Rini BI, Campbell SC, Escudier B: Renal Cell Carcinoma. *Lancet* 2009;373:1119-32.

Topic:

Oncology: Renal Tumors

Subtopics:

Etiology and Familial RCC