

IN THIS ISSUE

Tumor Board for Immune-Related Adverse Events [3](#) | Psoriatic Arthritis Treatment Guidelines [5](#) | Hypophosphatasia [6](#)
Inflammatory Eye Disease and Hidradenitis Suppurativa [8](#) | Psoriasis in a Patient with HIV-Related Kaposi Sarcoma [9](#)
Scleredema Adultorum of Buschke [10](#) | Cutaneous Vasculitis [12](#) | Leukopenia and Lupus [14](#)



Rheumatology Connections

An Update for Physicians | Summer 2019





From the Chair of Rheumatic and Immunologic Diseases



Cleveland Clinic's Rheumatology Program is ranked among the top 2 in the nation in *U.S. News & World Report's* "America's Best Hospitals" survey.

Dear Colleagues,

I am honored to present to you the summer 2019 issue of *Rheumatology Connections*, an issue I think is particularly representative of the interdisciplinary nature and broad implications of the medicine we practice as rheumatologists.

Our frequent collaborations with dermatology underscore the multisystemic nature of our specialty. Dr. Elaine Husni presents highlights of the first set of collaborative guidelines on psoriatic arthritis from the American College of Rheumatology and our dermatology colleagues in the National Psoriasis Foundation (p. 5). Dr. Leonard Calabrese's ustekinumab case spanning rheumatology, dermatology and oncology is the first of its kind reported (p. 9). Dr. Soumya Chatterjee offers a case study on the rare and debilitating scleredema adutorum of Buschke (p. 10). And Dr. Carol Langford co-authors a report on cutaneous vasculitis with a colleague in dermatology that offers important pearls for diagnostic accuracy (p. 12).

Of course, our multidisciplinary collaborations do not end with dermatology. Our first article features a collaboration with Cleveland Clinic Cancer Center to effectively identify and treat patients whose cancer treatment causes immune-related adverse events (p. 3). Dr. Rula Hajj-Ali describes her joint effort with colleagues in Cleveland Clinic's Cole Eye Institute to explore a relationship between inflammatory eye disease and hidradenitis suppurativa (p. 8). Dr. Emily Littlejohn and Dr. Cassandra Calabrese, the first graduate of our unique rheumatology and infectious disease combined residency program, offer insight into a common conundrum in our patients with systemic lupus erythematosus (p. 14). Dr. Chad Deal and I present an elderly patient living with what many consider primarily a pediatric disease (p. 6).

In addition to highlighting the multisystemic, collaborative nature of the work we do, this issue illustrates our commitment to Cleveland Clinic's tripartite mission of caring for the sick, investigating their conditions and educating those who serve. We hope these stories offer you an opportunity to connect, collaborate or consult with our team.

Respectfully,

Abby Abelson, MD

Chair, Rheumatic and Immunologic Diseases
216.444.3876 | abelsoa@ccf.org

Rheumatology Connections, published by Cleveland Clinic's Department of Rheumatic and Immunologic Diseases, provides information on leading-edge diagnostic and management techniques as well as current research for physicians.

Please direct any correspondence to:

Abby Abelson, MD

Chair, Rheumatic and Immunologic Diseases

Cleveland Clinic/A50
9500 Euclid Ave.
Cleveland, OH 44195
216.444.3876
abelsoa@ccf.org

Managing Editor: Deborah Booth Summers

Graphic Designer: Kim Conard

Illustration: Amanda Mendelsohn

Rheumatology Connections is written for physicians and should be relied on for medical education purposes only. It does not provide a complete overview of the topics covered and should not replace the independent judgment of a physician about the appropriateness or risks of a procedure for a given patient.

© The Cleveland Clinic Foundation 2019

Cover illustration: Checkpoint inhibitor therapy.

A Novel Tumor Board for Patients with Immune-Related Adverse Events

COLLABORATING TO TREAT THIS EMERGING COMPLICATION OF CPI

By Cassandra Calabrese, DO

CASE

A 62-year-old male presented to my rheumatology clinic for evaluation of joint and muscle pain in the setting of checkpoint inhibitor therapy (CPI) to treat his cancer. He was diagnosed with metastatic renal cell carcinoma in 2018. He received Gamma Knife® therapy to a brain lesion in early July 2018, then started combination CPI with ipilimumab (anti-CTLA-4) and nivolumab (anti-PD-1).

After his first infusion, he felt stirrings of pain in his hands involving the fingers and wrists. After the second infusion, this pain significantly worsened, and he developed swelling of the proximal interphalangeal joints, metacarpophalangeal joints and wrists. The elbows and shoulders were also painful with severe stiffness, to the point that he had difficulty performing his activities of daily living.

Prior to CPI, he had knee pain from advanced right knee osteoarthritis, but no other history of rheumatic or autoimmune disease. At presentation, his fingers and wrists were swollen. He was unable to make a fist, lift his shoulders or walk due to pain and stiffness. The laboratory workup revealed an erythrocyte sedimentation rate of 46 mm/hr, a C-reactive protein level of 2.4 mg/dL, negative rheumatoid factor and anti-CCP antibodies. He was

started on prednisone 15 mg daily, and within days his symptoms disappeared. He reported not having felt this good in the past two years. Prednisone was decreased to 12.5 mg two weeks later without worsening of symptoms.

Regarding his cancer treatment, after four cycles of combination therapy he was switched to monthly monotherapy with nivolumab, with plans to continue for the foreseeable future. After subsequent infusion, he had transient recurrence of joint pain and stiffness which have since resolved. He continues on prednisone 7.5 mg daily. At this point, I presented the patient's case at our immune-related adverse event (irAE) monthly tumor board to discuss next steps in management, because although his tumor was responding to CPI, the treatment was causing a debilitating rheumatic irAE.

This case highlights many important issues surrounding patients who develop rheumatic irAEs from CPI: What is the optimal treatment? Will the irAE persist? Is it safe to be on prednisone long term while receiving CPI? Our multidisciplinary tumor board was created to help answer challenging questions such as those generated by this case.



Dr. Calabrese (calabrc@ccf.org; 216.445.6996) is associate staff in the Department of Rheumatic and Immunologic Diseases, holds a joint appointment in the Department of Infectious Diseases, and is board-certified in rheumatology and infectious diseases.

The immune-related adverse events tumor board

In 2015, the Department of Rheumatic and Immunologic Diseases started seeing an influx of patients with rheumatic irAEs from CPI. At the time, very little was known about irAEs in general, and by 2016 we had established an interdisciplinary referral clinic with oncology to help manage these patients.

The number of patients increased, as did the uncertainty surrounding diagnosis and proper management of irAEs. This prompted creation of a multidisciplinary monthly

tumor board in September 2017. The goal of the tumor board is to discuss new and/or challenging cases of irAEs, review the extant literature and receive input on interprofessional management. The field of irAEs related to checkpoint inhibitor therapy is growing quickly, and multidisciplinary collaboration is crucial for patient care, as well as to advance our knowledge in the field.

A typical tumor board

Cleveland Clinic Cancer Center hosts the monthly meeting. In the beginning, mostly oncologists and

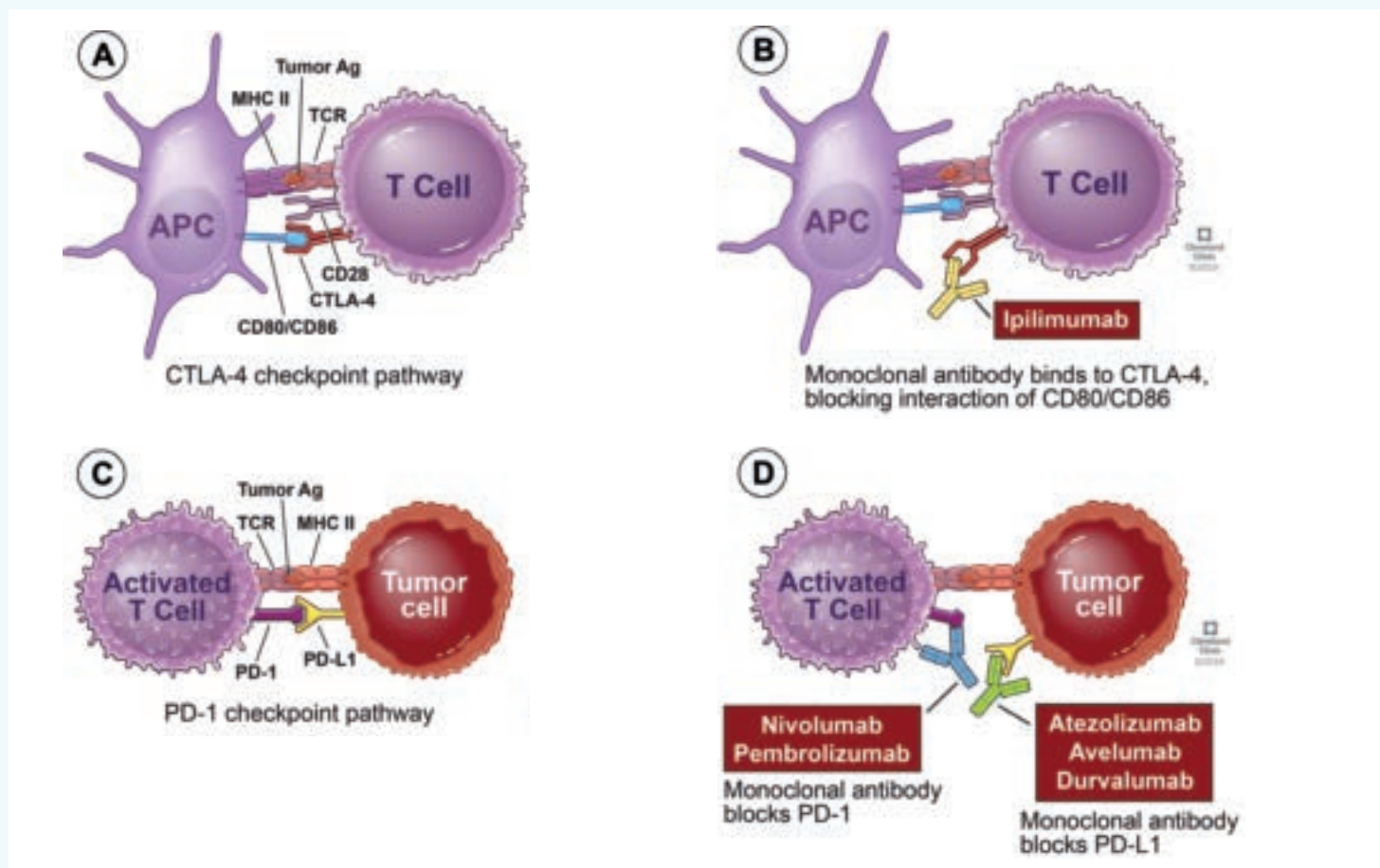


Figure. **A)** CTLA-4 is expressed on the T-cell surface and binds CD80/86 on the antigen-presenting cell to downregulate the early stages of T-cell activation. **B)** Blocking CTLA-4 with ipilimumab, an immune checkpoint inhibitor, enhances T-cell responses against the tumor. **C)** PD-1 binds to its ligand, PD-L1, in the periphery to downregulate the immune response. **D)** Blockade of PD-1 or PD-L1 by various checkpoint inhibitors reinvigorates the immune response.

rheumatologists attended. Now we have regular attendees from gastroenterology, ophthalmology, cardiology and pulmonology, depending on the cases presented. The week before the meeting, a coordinator from oncology emails the group asking for cases. Anywhere from three to six cases are presented per meeting, often accompanied by a discussion of the pertinent literature.

The cases presented are about equally split between interesting cases that we learn from in hindsight and cases with real-time decisions to make. For the latter, the gathering of multiple specialties has helped significantly in brainstorming and presenting data from the literature or past experiences.

The impact on interprofessional confidence and collaboration

At the 2018 American College of Rheumatology meeting, my

colleagues and I presented the impact of these novel irAE tumor boards on clinician confidence in managing irAEs. We surveyed past board participants on the educational value of the meetings as well as their perceived impact on awareness and confidence in management of irAEs. We found that two-thirds of providers felt far more aware of and confident in diagnosing and managing irAEs.

Anecdotally, we've all been surprised by how much everyone enjoys and looks forward to this monthly meeting. For many of us, it's our favorite conference, perhaps because it's an emerging and changing field, or perhaps because it demonstrates the benefit of a multidisciplinary approach to patient care. Either way, it has definitely benefited the growing number of patients we see with irAEs.

Joint ACR/NPF Psoriatic Arthritis Treatment Guidelines Emphasize Treat-to-Target Approach

CONDITIONAL RECOMMENDATIONS INCLUDE TNFI AS FIRST-LINE

A wealth of new treatments for psoriatic arthritis (PsA) in recent years has prompted the development of new treatment guidelines, released jointly by the American College of Rheumatology (ACR) and the National Psoriasis Foundation (NPF) in December 2018.¹

“It’s great that we have more treatment options for our patients, but until these guidelines, there was no evidence-based algorithm for how to use them,” says M. Elaine Husni, MD, MPH, staff in the Department of Rheumatic and Immunologic Diseases and a member of the guidelines committee. “These guidelines represent the best of what we have that’s evidence-based.”

But most of the recommendations remain conditional, she adds. “The data are limited. It’s not ethical to withdraw treatment, and we have few head-to-head trials, so we compiled a group of experts to deliver consensus-based statements to guide treatment.”

For the first time, that group of experts included patients with PsA. Two patients served on a voting panel with healthcare professionals, and a patient panel of nine adults with PsA provided insights on their experience, which were incorporated into panel discussions.

“The patient panel is novel for treatment guidelines and allows recommendations to be more representative of what patients really experience,” says Dr. Husni.

The guidelines also address treatment in the presence of comorbidities including inflammatory bowel disease, diabetes and serious infections and other issues like enthesitis, psoriatic spondylitis and vaccinations.

Impact and future directions

According to Dr. Husni, these guidelines move us closer to optimal treatments for inflammatory arthritis.

Notable recommendations

- Use a treat-to-target approach for all patients with active disease (conditional)
- Prescribe TNF inhibitor (TNFi) biologics as first-line therapy for treatment-naïve patients with active PsA (conditional)
- Choose oral small molecule (OSM) drugs for nonsevere disease, patient preference for oral therapy or contraindications to TNFi (conditional)
- Switch to a TNFi or an IL-17 or IL-12/23 inhibitor instead of another OSM if active disease persists with OSM therapy (conditional)
- Urge patients to quit smoking (strong)

“The treat-to-target approach has been well known in rheumatoid arthritis, but it now also has validity in psoriatic arthritis,” she says. “Couple this with the recommendation of TNF inhibitors as first-line treatment for treatment-naïve patients with active disease, and I think these guidelines will have lasting impact on how we treat our patients.”

Dr. Husni also urges more focus on nonpharmacologic approaches to treatment. The recommendation for smoking cessation is a significant step in the right direction, but more research is needed in other areas, such as the relationship between obesity and PsA. “We are also studying ways to decrease the primary comorbidities of the disease, including cardiovascular disease,” she adds. “There is always more to be done for our patients.”



Dr. Husni (husnie@ccf.org; 216.445.1853) is Director of the Arthritis & Musculoskeletal Treatment Center in the Department of Rheumatic and Immunologic Diseases.

1. Singh JA, Guyatt G, Ogdie A, Gladman DD, Deal C, Deodhar A, Dubreuil M, Dunham J, Husni ME, et al. 2018 American College of Rheumatology/National Psoriasis Foundation guideline for the treatment of psoriatic arthritis. *Arthritis Rheumatol*. 2019;71(1):5-32.

Multiple Fractures, Low ALP and High B6 in an Elderly Patient

DIAGNOSING AN INHERITED METABOLIC BONE DISEASE LATER IN LIFE

By Abby Abelson, MD, and Chad Deal, MD



Dr. Abelson
(abelsoa@ccf.org; 216.444.3876) is
Chair of the Department
of Rheumatic and
Immunologic Diseases.



Dr. Deal (dealc@ccf.org; 216.444.6575) is
Director of the Center
for Osteoporosis and
Metabolic Bone Disease.

CASE

A 69-year-old female presented to our Center for Osteoporosis and Metabolic Bone Disease with a recent history of multiple fractures and a family history of premature tooth loss. Her father was reported to have only one tooth left at time of death. Although the patient reported no premature tooth loss, her daughter lost six teeth before age 3. The patient's first fracture was a wrist at age 53, then an ankle at 54 and fibula at 55. At age 66, she fractured her right femur and then her left femur the following year, requiring bilateral medullary rods (Figure). A DXA scan showed a lumbar spine T-score of -0.9 and hip T-score of -2.4.

She was treated with alendronate sodium for four years in her 50s, teriparatide for two years and then several doses of denosumab. A chart review revealed that her alkaline phosphatase (ALP) levels had been consistently less than 40 IU/L. A vitamin B6 test revealed a level of 283 (normal < 125 nm/L). X-rays of the knees were ordered and showed chondrocalcinosis. Genetic sequencing of the ALP gene revealed a pathologic variant associated with previous cases of hypophosphatasia (HPP). The patient was started on asfotase alfa in November 2018.

The case illustrates late but severe disease manifestations of HPP. Treatment with antiresorptive agents was of no benefit and likely harmful. Patients with apparent osteoporosis and an ALP that is persistently below 40 IU/L should not be placed on an antiresorptive agent until the diagnosis of HPP is considered.

Disease prevalence

Hypophosphatasia (HPP) is a rare metabolic bone disease, with an estimated prevalence of between 0.3 and 1/100,000 in severe forms, with more recent reports suggesting that moderate forms are substantially more frequent.¹

A review of Cleveland Clinic medical records found more than 600 patients with at least two ALP < 30 readings with no value ever above 40. Clinical review of these patients is ongoing.

A retrospective review over 10 years of 885,165 patients at Marshfield Clinic found persistent hypophosphatasemia in 1 of 1,544 adult patients.² Many of these patients were found to harbor previously unrecognized HPP. These adult patients had more crystalline arthritis, orthopaedic surgery, chondrocalcinosis, calcific peri-arthritis, enthesopathy and diffuse idiopathic skeletal hyperostosis than a general adult patient population.

Disease etiology

In this inherited disease, mutations of the *ALPL* gene result in the reduction of tissue-non-specific isoenzyme of alkaline phosphatase (TNSALP) activity.

TNSALP is a cell-surface homodimeric phosphohydrolase that is richly expressed in the liver, kidney, skeleton and developing teeth. TNSALP substrates, including inorganic pyrophosphate (PPI) and pyridoxal 5-phosphate (PLP) (vitamin B6), accumulate extracellularly in HPP. PPI is a potent inhibitor of mineralization, and its excess in HPP explains many of the hard-tissue complications of HPP, including premature loss of deciduous teeth, rickets in children, osteomalacia in adults, chondrocalcinosis, frequent fractures and calcific arthropathies. PLP, the major cofactor form of vitamin B6, explains the pyridoxine-dependent seizures of severe HPP. In adults, elevated PLP does not result in clinical symptoms but is a biomarker for the disease, in addition to low ALP.

How your patient may present

Rheumatologists most commonly see the adult form of HPP, one of six major forms of the disease. The adult form is characterized by muscle pain, muscle weakness, recurring stress fractures, osteomalacia, a history of dental abnormalities and calcium pyrophosphate dihydrate crystal deposition in the cartilage.² Only a few small cohort studies characterize adult HPP in terms of clinical, radiographic and laboratory presentation.³

Clinicians should take notice of persistent hypophosphatasemia, consider the diagnosis of HPP and be cautious when considering potent antiremodeling therapy in these adults since the underlying disorder is a defect in mineralization (osteomalacia), not osteoporosis.

Treating HPP

Asfotase alfa (Strensiq®) has revolutionized the treatment of HPP. Asfotase alfa, a mineral-targeted recombinant TNSALP, was approved by regulatory agencies in many countries in 2015 for pediatric-onset HPP. Adult treatment is off-label, but since the disease is the result of a genetic variant present at birth, all cases are in essence pediatric, even though those with mild disease may first present for evaluation much later in life. Most of these patients will have had unrecognized disease manifestations in their youth, such as premature loss of primary teeth before the age of 5. The tooth loss is characterized by loss of the entire tooth with root intact and is a result of insufficient mineral in the cementum that covers the tooth and anchors the root to the periodontal ligament.

Prior to the availability of asfotase alfa, teriparatide had been used in several case reports with mixed success. Unlike an antiresorptive agent, an anabolic agent such as teriparatide is not likely to be harmful. Since the data on treatment with asfotase alfa are for children, the treatment of adults with HPP is less formulated. Shapiro and Lewiecki suggest treatment of adults be considered if one or more of the following are present and determined to be clinically significant and attributable to HPP:

1. Musculoskeletal pain requiring prescription pain medications, especially chronic opioids.

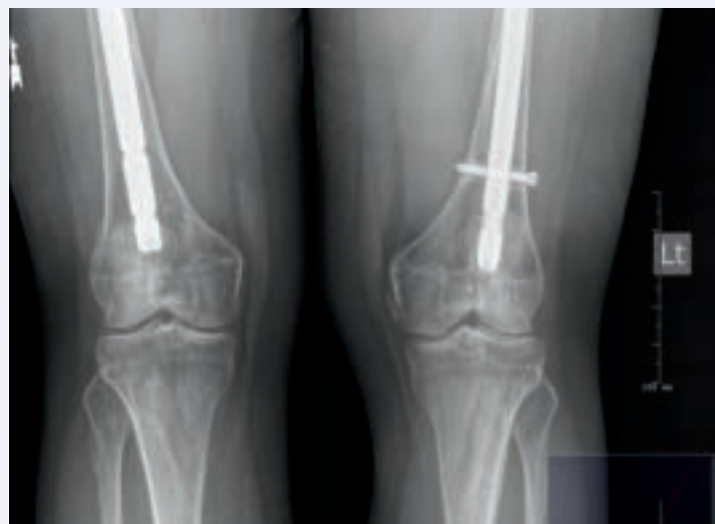

Figure: Bilateral femur fractures with rods. The knees show chondrocalcinosis.

2. Disabling polyarthropathy or chondrocalcinosis.
3. Major low-trauma fracture (e.g., spine, hip, humerus, pelvis) attributable to HPP.
4. Delayed or incomplete fracture healing or fracture nonunion.
5. Repeated episodes of orthopaedic surgery for complications of HPP, especially for nonunion and delayed union fractures.
6. Disabling functional impairment (e.g., mobility, gait, activities of daily living) assessed by validated measures.
7. Low bone mineral density by DXA: T-score -2.5 in postmenopausal women and men age 50 years or older, or Z-score -2.0 in younger adult women and men in patients with fractures.
8. Radiological evidence of nephrocalcinosis.

Over the past year we have diagnosed five new cases of HPP. Because our clinic is a referral center, our population would be enriched in a rare metabolic bone disease, but we suspect that one or more cases may be present in many rheumatologic practices, especially practices that evaluate and treat osteoporosis patients.

1. Mornet E, Yvard A, Talilandier A, et al. A molecular-based estimation of the prevalence of hypophosphatasia in the European population. *Ann Hum Genet.* 2011;75(3):439-445.
2. McKiernan FE, Berg RL, Fuehrer J. Clinical and radiographic findings in adults with persistent hypophosphatasemia. *J Bone Miner Res.* 2014;29(7):1651-1660.
3. Shapiro JR, Lewiecki EM. Hypophosphatasia in adults: clinical assessment and treatment considerations. *J Bone Miner Res.* 2017;32(10):1977-1980.

Inflammatory Eye Disease in Patients with Hidradenitis Suppurativa

CHARACTERISTICS AND OUTCOMES

By Rula Hajj-Ali, MD



Dr. Hajj-Ali (hajjalr@ccf.org; 216.444.9643) is Associate Director of the Center for Vasculitis Care and Research at Cleveland Clinic.

Patients with hidradenitis suppurativa (HS, acne inversa and historically Verneuil's disease) commonly present with abscesses, sinus tract formation, recurrent nodules and/or scarring primarily in the intertriginous areas. This inflammatory skin condition can cause profound morbidity, and HS has been reported to coexist with inflammatory eye disease (IED) in several cases. My colleagues in Cleveland Clinic Cole Eye Institute — Sunil Srivastava, MD, and Careen Lowder, MD, PhD — and I explored this association and patient outcomes in a recent report in the *European Journal of Rheumatology*.¹

Why the association?

The pathogenesis of HS is poorly understood, but the role of immune dysregulation is believed to be similar to that of Crohn's disease. Eye involvement is common in many inflammatory diseases, including Crohn's. Given the case reports demonstrating association between HS and IED, and the hypothesis that HS shares systemic inflammation dysregulation similar to Crohn's, we sought to explore the possibility that IED is a rare manifestation of HS.

We performed a retrospective chart review of Cleveland Clinic patients from January 2005 to January

2016 with HS and chronic IED. An independent ophthalmologist ensured the accuracy of IED diagnosis.

Of the 20 patients included in the final analysis, 13 had uveitis, six had scleritis and one had peripheral ulcerative keratitis. Sixty-five percent of patients had autoimmune and/or inflammatory comorbidities. Forty percent had inflammatory bowel disease; other comorbidities included rheumatoid arthritis, systemic lupus erythematosus, ankylosing spondylitis and multiple sclerosis. Treatments and remission rates were as follows:

- Topical steroids (85% treated, 29% remission)
- Tumor necrosis factor inhibitors (40% treated; 100% remission infliximab, 50% remission adalimumab)
- Methotrexate (35% treated, 29% remission)
- Systemic steroids (35% treated, 14% remission)

Association needs further exploration

Ultimately, our study is limited by its small size and retrospective nature, but it sheds further light on the multiple case reports linking HS and IED. The one-third of patients with IED but without any autoimmune or inflammatory comorbidity appears to support our hypothesis of a common pathogenic link between the two. We also don't have enough data to recommend a course of treatment for patients, though most of our patients (70 percent) did not respond to first-line therapy (topical steroids) and required escalation to systemic immunosuppressive agents.

This association deserves further attention from larger studies, but for now, clinicians should remain aware of a possible association between HS and IED, perhaps arising from similar immune dysregulation phenomenon as those linking Crohn's and HS.

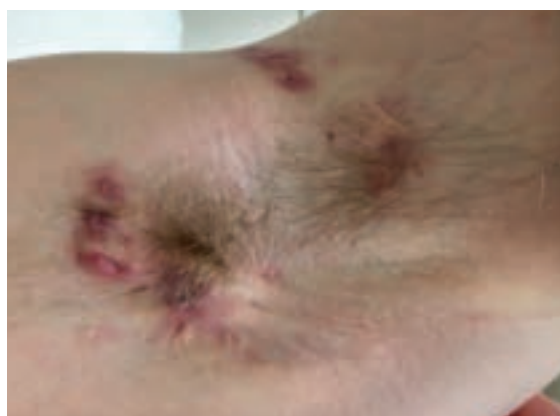

Figure. Inflamed nodules with multiple sinus tracts and comedones in patient with hidradenitis suppurativa.

1. Saygin D, Syed AU, Lowder CY, Srivastava S, Maya JJ, Hajj-Ali RA. Characteristics of inflammatory eye disease associated with hidradenitis suppurativa. *Eur J Rheum.* 2018;5(3):165-168.

Ustekinumab for Psoriasis in a Patient with HIV-Related Kaposi Sarcoma

FIRST REPORTED CASE

By Leonard Calabrese, DO

Presentation

A 55-year-old man with a 30-year history of plaque-type psoriasis developed disease covering 75 percent of his body surface area after being diagnosed with HIV in 2004. His physicians avoided immunosuppressants for his psoriasis and instead used a combination of narrowband ultraviolet B phototherapy and acitretin 10 to 30 mg daily, but improvement was mild at best. The patient was diagnosed with Kaposi sarcoma (KS) in 2008; imiquimod 5% cream halted its progression.

The patient's HIV and KS were stable, but his psoriasis remained significant. A number of reports have shown that biologics are safe and effective in treating HIV-associated psoriasis, so we began treating him with ustekinumab in July 2016. His first dose of 45 mg led to almost complete clearance with no change in KS at four weeks, the time of his second ustekinumab dose. Every 12 weeks, the patient received an additional dose until his final follow-up in October 2017 (Figure). His psoriasis remained nearly cleared, and KS lesions

and CD4 counts remained stable with no negative impact on viral load or opportunistic infections. My colleagues Anthony Fernandez, MD, PhD; Cassandra Calabrese, DO; and I published this report in *Clinical and Experimental Dermatology*.¹

Biologics for immunocompromised patients

Patients with immunological dysfunction can experience cutaneous diseases, including psoriasis vulgaris and KS. KS is the most common tumor associated with HIV and is an incurable and potentially fatal malignancy. Psoriasis is often refractory to standard treatments in patients with HIV.

A growing collection of case reports and series support the use of biologic agents for HIV-associated psoriasis, including ustekinumab, an IL-12/IL-23 inhibitor. Because IL-12 is a proinflammatory cytokine that has been explored as a treatment for HIV-associated KS, use of a drug that inhibits IL-12 could potentially promote KS progression. Significantly, our patient's KS

remained stable after 16 months.

Our case is the first reported that treats an HIV-positive patient with both severe psoriasis and KS with ustekinumab and suggests that the biologic may be a safe and effective treatment for patients with HIV-associated KS and psoriasis.



Dr. Calabrese (calabrl@ccf.org; 216.444.5258) directs the R.J. Fasenmyer Center for Clinical Immunology and is Vice Chair of the Department of Rheumatic and Immunologic Diseases.

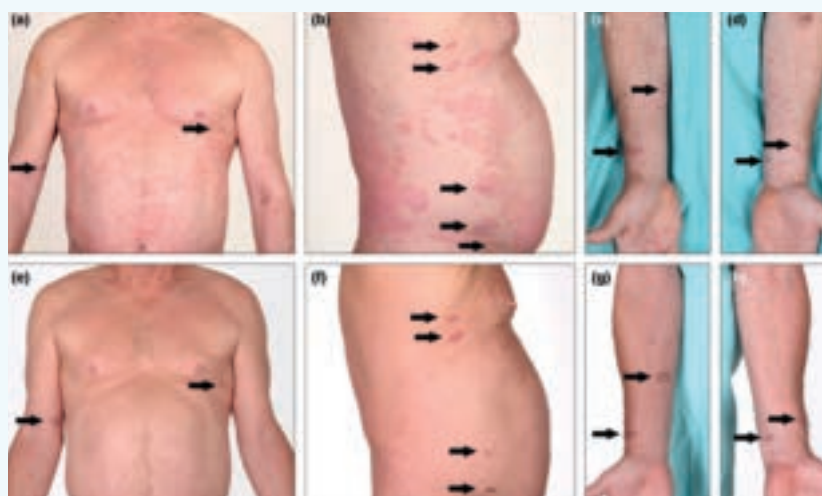

Figure. A-D. Patient in May 2016, just before initiation of ustekinumab treatment. Kaposi sarcoma (KS) lesions are denoted by arrows. **E-H.** Patient in September 2017, after 15 months of ustekinumab treatment. The KS lesions were unchanged compared with before initiation of ustekinumab treatment.

1. Wang DM, Fernandez AP, Calabrese CM, Calabrese LH. Treatment of psoriasis with ustekinumab in a patient with HIV-related Kaposi sarcoma. *Clin Exp Derm.* 2019;44(1):113-115.

Dysphagia and Woody Induration of Skin in a Patient with Type 2 Diabetes

WHAT IS THE DIAGNOSIS?

By Soumya Chatterjee, MD, MS, FRCP



Dr. Chatterjee
(chattes@ccf.org;
216.444.9945) directs
the Scleroderma Program
in the Department
of Rheumatic and
Immunologic Diseases.

A 54-year-old woman presented to our general rheumatology clinic with widespread skin induration on her face, neck, anterior and posterior chest wall, proximal and distal upper extremities, abdominal wall and thighs (Figure 1). She had a history of poorly controlled Type 2 diabetes mellitus on long-term insulin as well as an immunoglobulin G lambda monoclonal gammopathy.

She described a feeling of tightness in the skin and stiffness in the nape of her neck that made it difficult to tuck her chin during swallowing. She also experienced difficulty initiating and completing swallowing both liquids and solids, regardless of consistency. She even experienced difficulty swallowing saliva, which led to frequent coughing, choking and subsequent hoarseness, indicating possible microaspirations. Eating quickly tired her, and she had early satiety, resulting in an unintentional weight loss of 10 pounds in a year. She denied heartburn.

Her gait was normal. She denied paresthesias and showed no evidence of diabetic peripheral or autonomic neuropathy and no ophthalmoscopic evidence of diabetic retinopathy.

Pinpointing the source

A punch biopsy of the skin on her left upper back revealed absence of fibroblastic proliferation but indicated increased spaces between the collagen bundles of the reticular dermis, associated with increased dermal mucin. These are characteristic features of scleredema.

Her labs showed elevated fasting blood glucose and persistent glycosuria. She had a normal CBC, metabolic panel and urinalysis. A swallow study showed mild oral-phase and mid-moderate pharyngeal-phase swallowing deficits.

Standard barium swallow identified a diffusely narrow esophageal caliber and motility that indicated aperistalsis. The barium tablet only cleared past the transverse aorta after several swallows of water and then obstructed again at the lower esophageal sphincter. The findings on barium swallow resembled the abnormalities seen in achalasia (Figure 2).

Esophageal manometry revealed markedly abnormal motility in the distal two-thirds of the esophagus and total absence of the primary peristaltic wave. Of 10 swallows, only four showed normal peristalsis in the body of the esophagus (five weak, one failed). The study also revealed low resting pressure with normal relaxation in the lower esophageal sphincter. Esophagogastroduodenoscopy confirmed decreased motility.

A solid meal gastric-emptying study ruled out gastroparesis as the cause of her early satiety. We attributed this instead to scleredematous involvement of the skin of the anterior abdominal wall, preventing gastric expansion after meals.

Scleredema adultorum of Buschke

Three common sclerosing skin conditions have been associated with dysphagia due to oropharyngeal and esophageal dysmotility: systemic sclerosis, scleromyxedema and chronic sclerodermatous graft-versus-host disease. This is the first reported case of significant symptomatic dysphagia in a fourth sclerosing skin disorder, scleredema adultorum of Buschke. These four conditions show significant differences in dermal pathology but have all been associated with dysphagia, indicating a potential mechanical problem leading to stiffness or atrophy of the pharyngeal and esophageal musculature across the underlying etiologies.

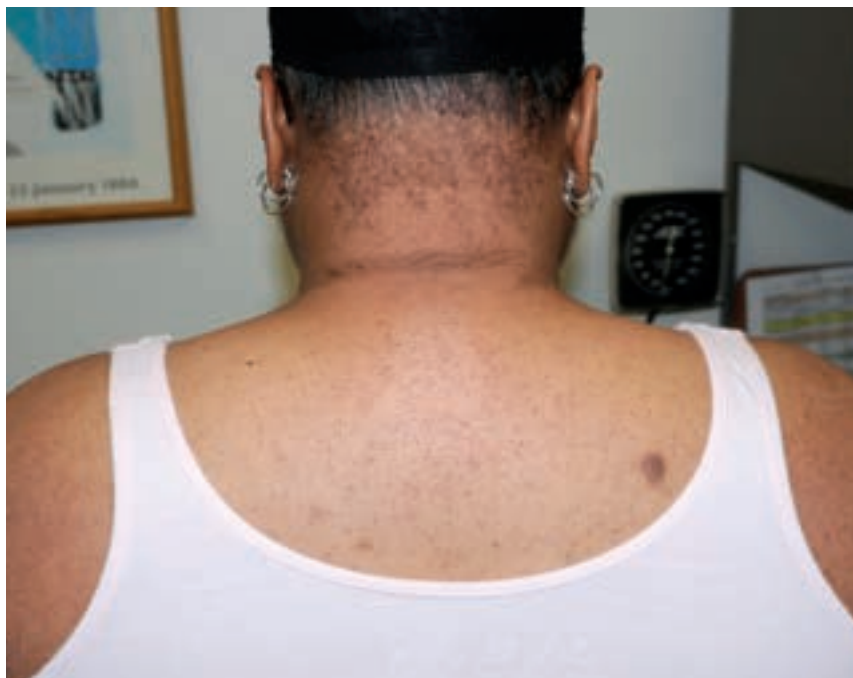

Figure 1. A 54-year-old woman with scleredema. Indurated skin on the nape of neck, upper back and arms.

Patients with diabetic autonomic neuropathy also can experience esophageal motility disorders, but this patient had no evidence of autonomic neuropathy.

Clinical course

Our approach included speech pathology and more aggressive management of her diabetes. Prior reports have shown occasional partial reversal of cutaneous scleredema with better glycemic control, so we were hopeful that her dysphagia would improve. Unfortunately, although her weight is unchanged, the severity of her dysphagia has not decreased.

This case of scleredema adultorum of Buschke is the first in the literature to exhibit severe dysmotility involving the smooth and striated muscle of the entire esophagus. More studies are needed in order to offer these patients effective therapies.

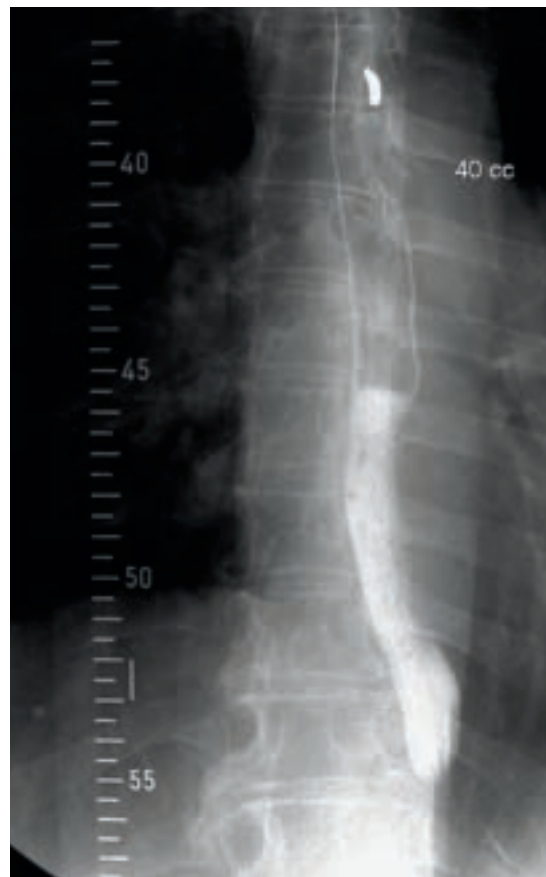


Figure 2. Standard barium swallow shows a diffusely narrow esophageal caliber. Reprinted with permission from Chatterjee S, Hedman BJ, Kirby DF. An unusual cause of dysphagia. *J Clin Rheum.* 2018;24(8):444-448.

Cutaneous Vasculitis — More than Skin Deep

KEY ASPECTS IN FOCUSING THE ASSESSMENT

By Carol A. Langford, MD, MHS, and Anthony P. Fernandez, MD, PhD



Dr. Langford (langfoc@ccf.org; 216.445.6056) is Director of the Center for Vasculitis Research at Cleveland Clinic as well as Vice Chair for Research, Department of Rheumatic and Immunologic Diseases.



Dr. Fernandez (fernana6@ccf.org; 216.445.8776) is Director of Medical Dermatology in the Dermatologic & Plastic Surgery Institute.

A 42-year-old female presents with a three-week history of a purpuric rash. On examination, numerous 2-3 mm nonblanching erythematous skin lesions are present on her bilateral lower extremities. She states that individual lesions resolve after four to five days, but new lesions continue to appear. You are suspicious that she has a cutaneous vasculitis. What should be the next steps in your assessment?

Cutaneous vasculitis is the most common vasculitic manifestation encountered in clinical practice. Although this frequently manifests as palpable purpura, it can have a wide range of appearances (Figure 1). In over 70 percent of patients, cutaneous vasculitis will be due to a medication, infection, malignancy, an underlying inflammatory disease or a primary systemic vasculitis. In the remaining 30 percent, this presents as an isolated cutaneous vasculitis in which no other organs are affected and there is no evidence of a linked cause.

When a cutaneous vasculitis is suspected, assessment should focus on three goals: 1) rule out vasculitis that is threatening a critical organ; 2) confirm that this is

vasculitis; 3) identify an underlying trigger or disease where possible.

Detection of organ-threatening vasculitis is based on information from the history, physical examination, labs and imaging. Although most vasculitic involvement of most organ sites will have associated symptoms or signs, these may not be present with lung or kidney involvement. In the case of pulmonary vasculitis, up to 30 percent of patients can have radiographic abnormalities despite the absence of other clinical features. With renal vasculitis, the patient may look and feel well and yet have active glomerulonephritis that places them at risk of renal failure.

The medical history can provide clues regarding affected organ sites, a trigger or an underlying disease. The medication assessment should include not only newly prescribed medications, but also over-the-counter agents, supplements and recreational substances. Physical examination is important in detecting objective evidence of tissue inflammation. For locations such as the upper airways, eyes, nerve, large blood vessels or skin, examination is the primary means through which active disease is evaluated. Laboratory testing should include a complete blood count with differential, chemistries (renal and hepatic function), acute phase reactants (sedimentation rate and/or C-reactive protein) and a urinalysis. Other studies such as antineutrophil cytoplasmic antibodies (ANCA), antinuclear antibodies (ANA), cryoglobulins or blood cultures should be guided by features that suggest an associated diagnosis. Chest radiography should be obtained in all patients with cutaneous vasculitis, even in the absence of pulmonary symptoms.

A skin biopsy of lesions suspicious for vasculitis should be performed in adult patients where the diagnosis is unknown (Figure 2). Biopsy can not only confirm vascular inflammation but can rule out other etiologies

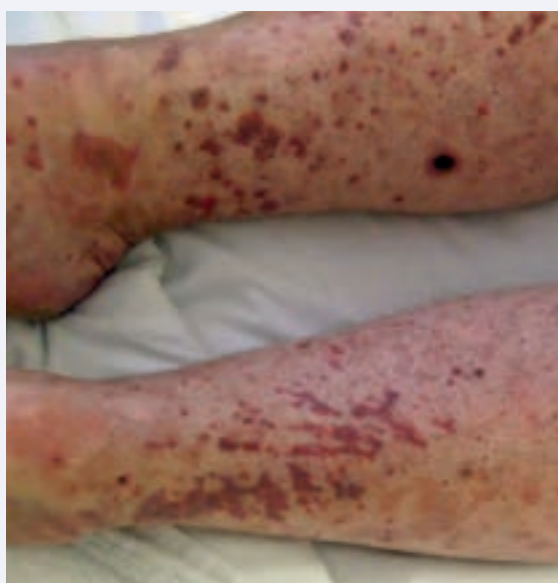

Figure 1. Coalescing purpuric lesions involving the lower extremities in a patient with cutaneous vasculitis.

that may have a similar appearance. In addition to standard histology, there should be consideration of performing immunofluorescence studies on the biopsy. IgA vasculitis (Henoch-Schönlein) is most frequently seen in children, but it can also occur in adults where the detection of IgA within compatible skin lesions can be helpful in securing the diagnosis. As immunofluorescence cannot be performed on formalin fixed tissue, this must be considered at the time the biopsy is obtained in order for the sample to be processed correctly.

Once vasculitis of the skin is confirmed, therapy is directed towards the underlying cause. For patients where cutaneous vasculitis is occurring secondarily, removing the trigger or managing the underlying disease will typically address the skin vasculitis as will treating an active primary systemic vasculitis.

For isolated cutaneous vasculitis, the optimal management approach has not been established. As this is not life-threatening, the goal is to use the least toxic yet effective therapy, balancing the risks of the medication against the risks of the vasculitis and its impact on quality of life. For asymptomatic skin lesions, observation and monitoring can be an appropriate option. When the cutaneous vasculitis is symptomatic and recurrent, commonly used agents include colchicine, dapsone, hydroxychloroquine and pentoxifylline. Immunosuppressive medications such as azathioprine or methotrexate can also be considered, particularly when disease is recurrent despite nonimmunosuppressive options. There is currently no good evidence suggesting one treatment is more effective than others.

Cleveland Clinic is participating in a randomized trial being conducted by the NIH-funded Vasculitis Clinical Research Consortium (VCRC) that seeks to determine the comparative efficacy of azathioprine, colchicine and dapsone in cutaneous vasculitis (ARAMIS). A concurrent study of skin biopsies seeks to better understand the pathophysiologic mechanisms occurring in vasculitis of the skin (CUTIS).

For our patient, on careful history she commented on weight loss, fatigue, and new nasal congestion and epistaxis that was worsening. On examination, her nasal membranes had an ulcerated appearance. She underwent a skin biopsy that demonstrated a leukocytoclastic vasculitis that was negative for IgA. Based upon her collective features, granulomatosis with polyangiitis was within the differential

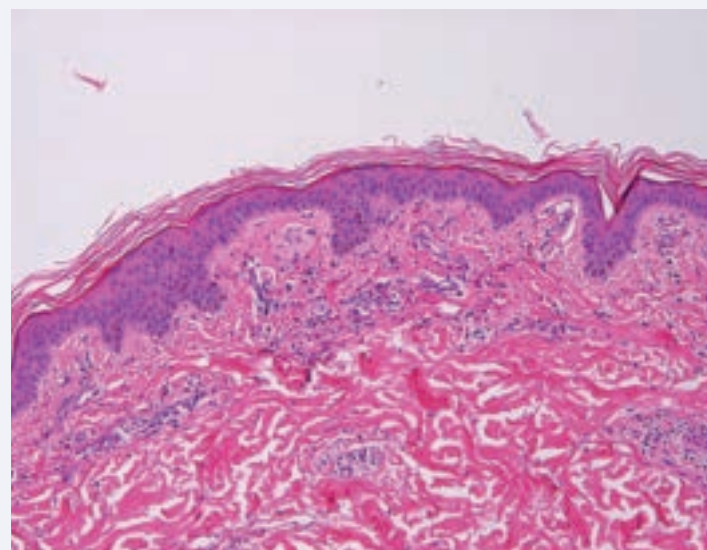


Figure 2. Histopathology of cutaneous vasculitis demonstrating perivascular and interstitial neutrophilic infiltrates, with leukocytoclasia, and extravasated erythrocytes consistent with a leukocytoclastic vasculitis.

and serologic testing was performed that revealed a positive proteinase 3 ANCA with a cytoplasmic staining pattern on indirect immunofluorescence (cANCA). Urinalysis and chest radiography were normal. The patient was treated with prednisone and methotrexate on which her cutaneous and upper airways disease went into remission.

Effective diagnosis and management of patients with cutaneous vasculitis requires a multidisciplinary approach that begins with the physician to whom the patient first presents and then includes the dermatologist and rheumatologist. The keys to a successful outcome include recognition of cutaneous vasculitis and its potential systemic associations, prompt assessment to confirm the diagnosis and to rule out critical organ involvement, and consultative referrals as are clinically indicated.

At Cleveland Clinic, the collaborative relationship between dermatology and rheumatology has been essential, not only in vasculitis but across a broad range of rheumatic diseases where cutaneous features can occur. By enhancing clinical care and research, these collaborations are advancing knowledge that benefits patients.

Leukopenia: Lupus Flare, Medication Effect or Infection?

HOW TO TELL THE DIFFERENCE ... AND WHY

By Emily Littlejohn, DO, MPH, and Cassandra Calabrese, DO



Dr. Littlejohn
(littlee3@ccf.org;
216.445.5559)
is associate staff
in the Department
of Rheumatic and
Immunologic Diseases.



Dr. Calabrese
(calabrc@ccf.org;
216.445.6996)
is associate staff
in the Department
of Rheumatic
and Immunologic
Diseases, holds a
joint appointment in
the Department of
Infectious Diseases,
and is board-certified
in rheumatology and
infectious diseases.

CASE

A 22-year-old female with systemic lupus erythematosus (SLE) is evaluated for leukopenia with predominant lymphopenia. Her lupus has manifested with pericardial effusions, thrombocytopenia and lupus nephritis, and she is on hemodialysis. Her serologies show positive antinuclear antibodies (ANA), positive anti-double stranded DNA (dsDNA) and hypocomplementemia. In 2017, she started azathioprine 50 mg daily, which was increased to 100 mg several months later, along with hydroxychloroquine. She has had several infectious complications, including line-related bloodstream infections. In March 2017, her white blood cell count (WBC) was 5.14 cells/ m^3 with absolute lymphocytes 1.24 cells/ m^3 . In August 2017, her WBC remained stable while lymphocytes fell to 0.62 cells/ m^3 ; this level has waxed and waned, as low as 0.23 cells/ m^3 . She now presents with worsening fatigue and increased arthralgias.

This case exemplifies the conundrum of leukopenia in SLE: Is the leukopenia caused by underlying SLE activity? Or perhaps by her SLE treatment? An infection? Or a combination of factors?

Rheumatologists are no strangers to leukopenia, as they monitor complete blood counts (CBCs) daily to analyze the inner workings of the immune system, the absolute number of peripheral cells, and the functioning or response of the bone marrow and thymus. The differential for leukopenia in a patient with autoimmune connective tissue disease includes underlying disease activity, medications, side effects and infection.

Disease activity

Leukopenia can be an important reflection of disease activity, occurring in almost half of patients with SLE.¹

In fact, the American College of Rheumatology and the Systemic Lupus International Collaborating Clinics include leukopenia in the classification criteria for SLE.

Although the majority of white blood cells are neutrophils, leukopenia can reflect a total decrease in neutrophils or a selective reduction in lymphocytes. Studies have shown that T and B cells correlate with clinical lupus disease activity and treatment. More specifically, a relative and absolute decrease in T lymphocytes has been found in active lupus, with the absolute number of B cells decreased to a lesser extent.² Another study showed correlation of antilymphocyte antibodies with lymphopenia in active SLE, thus demonstrating a clear association of increased antilymphocyte antibody activity and SLE exacerbation.³

Many factors have been suggested to play a role in decreased peripheral neutrophils in SLE, including neutralizing autoantibodies against growth factors that act on neutrophils, bone marrow suppression, autoantibody-driven cell removal and death by NETosis.^{4,5} One study showed that SLE serum stimulated oxygenation activity when incubated with normal neutrophils based on a chemoluminescence (CL) response. Interestingly, the percent CL response correlated with other measures of disease activity in SLE blood such as dsDNA antibodies and complement component 1q (C1q)-binding immune complexes (IC).⁶ The implications of this work are twofold: IC-driven neutropenia is related to underlying SLE activity and can increase susceptibility to infection.

Medication side effects

Of all the immunosuppressive therapies used to treat SLE, glucocorticoids (GCs) carry the strongest associated risk of infection.⁷ GCs have numerous effects on various WBC populations, as they function mainly by interfering with access of neutrophils and macrophages to sites of inflammation. Within four to six hours of administration, GCs cause a neutrophilic leukocytosis due in part to accelerated release from bone marrow, followed by a

transient lymphopenia, mainly due to redistribution out of circulation.

Lymphopenia and GC use are known risk factors for infections in SLE patients. In a single-center retrospective study of incidence of *Pneumocystis jirovecii* pneumonia (PJP), Godeau et al. reported 34 cases over 10 years, of which 94 percent were receiving GC and 91 percent were lymphopenic ($< 1.5 \times 10^9$) at the time of PJP diagnosis.⁸ Lymphopenia has been observed in several other studies in SLE patients with PJP. Experts recommend PJP prophylaxis in SLE patients receiving prednisone ≥ 30 mg daily.⁹

The prodrugs

Azathioprine (AZA) is a prodrug that depresses bone marrow function in a dose-dependent fashion, with increasing effects over time.¹⁰ With chronic administration, development of megaloblastosis may precede worsening cytopenias. Because the immunosuppressive properties of

AZA are mainly achieved by cytotoxic effects on T lymphocytes, some degree of lymphopenia can be interpreted as medication efficacy rather than an adverse event.

Another prodrug, mycophenolate mofetil (MMF), causes decreased B- and T-cell proliferation with variable frequencies of leukopenia.¹¹

Cyclophosphamide (CYC), also a prodrug, is sometimes given to induce a goal leukocyte count of 2 to 3 k/uLs. Similar to AZA mechanistically, this lowered count is an anticipated and expected drug effect that can reflect appropriate (therapeutic) immunosuppression.

The important clinical question is whether the associated cytopenias from use of this medication portend a significant infectious risk. Much of the data to shed light on this question come from the inflammatory bowel disease (IBD) population, where azathioprine is widely used. In one study of a large IBD cohort, 385 patients were on AZA, with 100 cases of lymphopenia (defined as $< 1,500$ lymphocytes/uL). Of these 100 cases, nine patients had opportunistic infections. Infections were not significantly more frequent in the subgroup with the nadirs between 200 and 499 C/ μ L than in the group with counts at 1,000 to

1,499 C/ μ L. In fact, opportunistic infections were not observed in the patient group with severe lymphopenia (< 200 C/ μ L).¹²

These findings are in contrast to a study examining 97 patients with chronic inflammatory diseases receiving methotrexate, AZA, or CYC with or without GC. Total lymphocyte counts were markedly decreased in patients receiving GC at doses > 10 mg prednisolone equivalent per day, or combination immunosuppressive therapy with cytotoxic drugs and GC at various doses.¹³ T-helper lymphocyte count $< 250/\mu$ L best predicted subsequent hospitalizations for infections, suggesting that low T-helper cell counts, regardless of their pathogenesis, can

predict infections.

Some degree of lymphopenia
can be interpreted as
medication efficacy.

Infection

There are numerous infectious causes of cytopenias. Viral infections known to cause leukopenia include Epstein-Barr virus, cytomegalovirus and human immunodeficiency virus, to name a few.¹⁴ Parvovirus B19 classically causes aplastic

anemia in immunocompromised patients; however, it can also cause symptoms (fever, arthralgia) that resemble a lupus flare, and rarely can cause pancytopenia, further complicating the patient assessment.¹⁵

In this case, an underlying flare

We ultimately determined that an underlying lupus flare caused our patient's lymphopenia, rather than her immunosuppressive regimen or an infection. She was admitted to the hospital and obtained high doses of steroids for serositis. She clinically improved, and her lymphopenia also improved, despite continued use of azathioprine.

This case exemplifies the complexities faced when differentiating among infection, medication effect and lupus activity. It is important for physicians to understand that leukopenia, regardless of cause, will increase risk of infection, and that in many cases, there is high likelihood of both autoimmune and infectious processes occurring concomitantly. When dealing with leukopenia in this setting, a heightened awareness of the risk of infection, close monitoring of CBCs while on high-risk medication and thorough evaluation for disease activity are crucial.

See reference list at consultqd.clevelandclinic.org/leukopenialupus.



The Cleveland Clinic Foundation
9500 Euclid Ave. | AC311
Cleveland, OH 44195

24/7 Referrals

855.REFER.123 (855.733.3712)

clevelandclinic.org/refer123

OUTCOMES DATA

View Outcomes books at
clevelandclinic.org/outcomes.



CME Opportunities: Live and Online

Visit ccfcmec.org for convenient learning opportunities from Cleveland Clinic's Center for Continuing Education.

Stay Connected with Cleveland Clinic's Orthopaedic & Rheumatologic Institute

CONSULT QD

News, research and perspectives from Cleveland Clinic experts.
consultqd.clevelandclinic.org/topics/rheumatology-immunology



Facebook.com/CMECClevelandClinic



[@CleClinicMD](https://twitter.com/CleClinicMD)



clevelandclinic.org/MDlinkedin



clevelandclinic.org/rheum