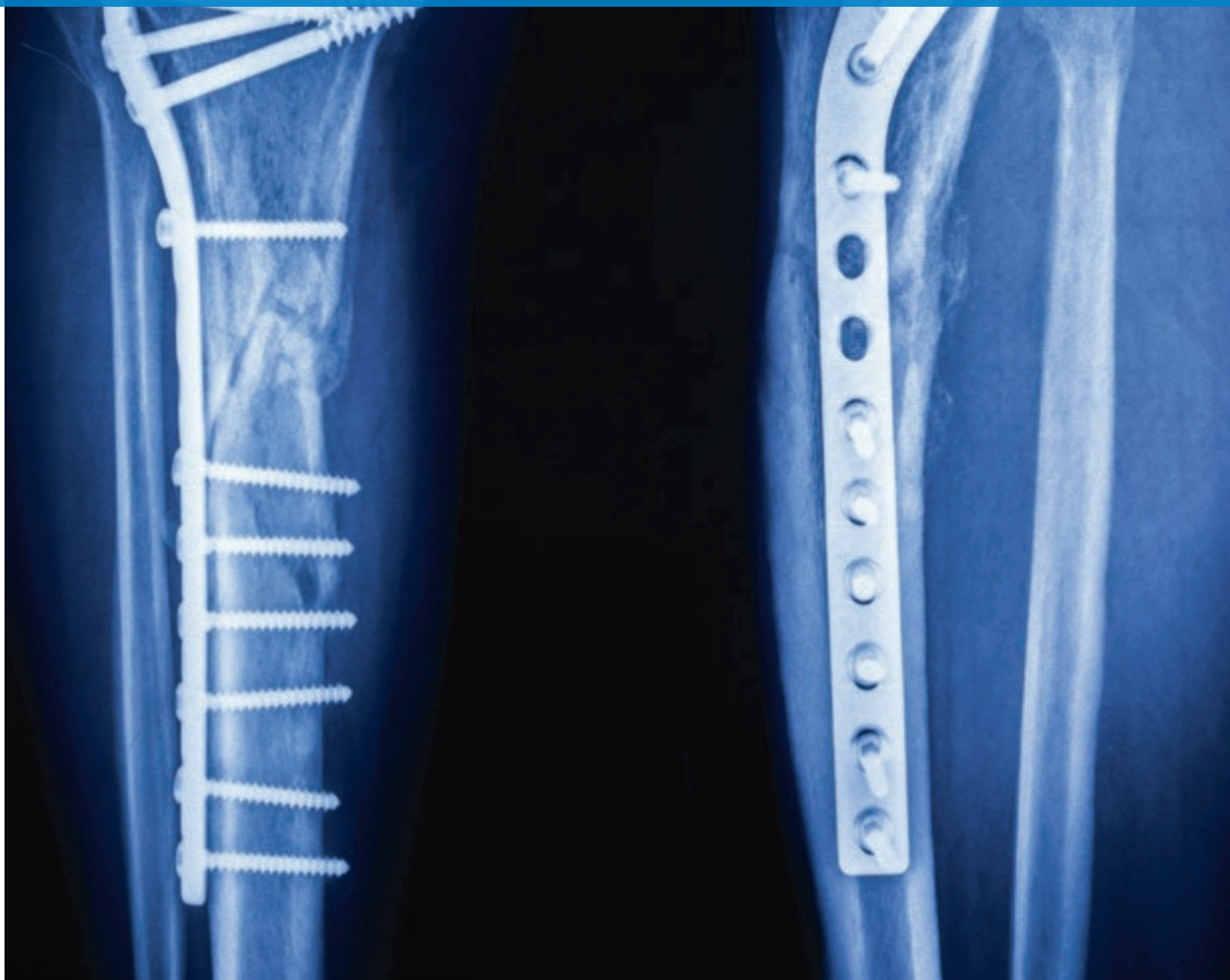




# ORTHOPAEDIC INSIGHTS

WINTER 2021

NEWS AND INSIGHTS FROM  
THE DEPARTMENT OF ORTHOPAEDIC SURGERY



# DEAR COLLEAGUES



I'm pleased to report that the clinicians and researchers in Cleveland Clinic's Department of Orthopaedic Surgery continue to move our specialty forward, even as the healthcare profession manages the worldwide pandemic. We are

committed to finding innovative solutions to patients' problems, using the most advanced techniques, within a team-of-teams framework that emphasizes accountability and outcomes. This issue of *Orthopaedic Insights* emphasizes the value of this collaborative approach, exploring a broad range of topics, including:

- Our cover story, which describes and compares the approaches to the challenge of rebuilding long bones in patients with diaphyseal bone tumors.
- How using both biologic and mechanical techniques to treat a patient with avascular necrosis of the knee allowed him to complete a triathlon only a year later.
- Introducing a much-needed calculator that can accurately predict the likelihood of improved pain, function, and quality of life one year after knee arthroplasty as well as length of stay and readmission.
- A detailed look at the factors—including implant position—that predict outcomes for total shoulder arthroplasty.

- How musculoskeletal virtual care is driving the digital transformation of orthopaedics.

If there is anything we've learned over the past several months, it's the great potential of virtual patient care across digital platforms to improve patient experience and reduce costs. Although a great deal of work remains to be done to align distance medicine with patient and provider needs, you can be sure that Cleveland Clinic's Department of Orthopaedic Surgery will be at the leading edge of virtual care. You can read about our progress, and much more, in this and future issues of *Orthopaedic Insights*.

Thank you for your interest in *Orthopaedic Insights*. Please don't hesitate to contact us for consults or referrals. We are here to serve you and your patients with the most advanced, team-based orthopaedic care, backed by the knowledge and resources of one of the world's great medical centers.

Respectfully,

BRENDAN M. PATTERSON, MD

Chairman, Orthopaedic Surgery

216.445.4792 | [patterb2@ccf.org](mailto:patterb2@ccf.org)



**Subscribe to *Orthopaedic Insights* eNews to learn about the latest innovations, research and educational programs from Cleveland Clinic:**  
[clevelandclinic.org/orthoinsights](https://clevelandclinic.org/orthoinsights).

## ORTHOPAEDIC INSIGHTS | WINTER 2021

*Orthopaedic Insights* is published by Cleveland Clinic's Department of Orthopaedic Surgery to inform musculoskeletal specialists about advances in diagnosis, medical and surgical management and research.

**Brendan M. Patterson, MD**

Chairman, Department of Orthopaedic Surgery

**Katie Contrera**, Managing Editor

**Michael Viars**, Art Director

**Center for Medical Art and Photography**, Imagery

**Beth Lukco**, Marketing Manager

*Orthopaedic Insights* is written for physicians and should be relied on for medical education purposes only. It does not provide a complete overview of the topics covered and should not replace a physician's independent judgment about the appropriateness or risks of a procedure for a given patient.

© 2020 The Cleveland Clinic Foundation

# PATIENT WITH MULTIFOCAL AVASCULAR NECROSIS UNDERGOES HIP AND KNEE PRESERVATION SURGERIES, COMPLETES TRIATHLON 1 YEAR LATER

## ORTHOPAEDIC SURGEON DISCUSSES COMPLEX CASE

In 2018, a 30-year-old male presented to Cleveland Clinic's Center for Hip Preservation with a known history of multifocal avascular necrosis (AVN). Having undergone prior treatments by Atul Kamath, MD, for hip and knee issues, the patient recently presented with varus malalignment and AVN of the knee, causing pain and disrupting his active lifestyle. He had thus far recovered successfully from prior treatments under the direction of Dr. Kamath: left hip arthroscopy, bilateral hip core decompression with biologic augmentation, and combined allograft osteochondral transplant and high tibial osteotomy of the right knee.

AVN, also known as osteonecrosis, is a condition caused by a lack of blood supply to the bone tissue, commonly the femoral head. There are numerous etiologies for this disease, with severe multifocal disease a less common presentation. Some studies estimate that around 20,000 to 30,000 cases of AVN are diagnosed in the U.S. each year.<sup>1</sup>

The patient, a former Marine and marathoner, was diagnosed with multifocal AVN a few years prior to his clinical encounter at Cleveland Clinic. Prior to Dr. Kamath's initial encounter with the patient, he had undergone two knee decompression surgeries but had continued knee pain. Evaluation during the initial encounter confirmed AVN lesions of the left knee without collapse of the articular surface—in conjunction with varus malalignment—and joint preservation surgery was recommended for his left knee.

The treatment plan for the left knee included a high tibial osteotomy (Figure 1) to realign the mechanical axis, core decompression of femoral and tibial lesions to improve blood flow and attempt to slow progression of AVN, with harvest of autologous bone marrow concentrate, and a Subchondroplasty® Procedure (SCP®) to augment bone edema lesions.

### A complex, multi-procedural approach

The high tibial osteotomy was performed to shift the weight-bearing line from the medial compartment of the knee to the desired position in the lateral compartment consistent with the preoperative plan. A biplanar cutting

jig was used to maintain coronal and sagittal plane deformity correction parameters (Figures 2A, 2B). Final anteroposterior and lateral knee views and long-limb intraoperative imaging revealed excellent alignment and bone graft technique.

Attention was then turned to the AVN treatment portion of the procedure, including core decompression. An aspiration of bone marrow was performed first using specialty needles coated with a heparin solution to prevent cell clotting. Multiple parallel bone cortex access sites were utilized to increase the yield of cells. This bone marrow was aspirated slowly to avoid trauma to the aspirated cells. The bone marrow solution was placed in a centrifugation system to produce bone marrow concentrate suitable for injection.<sup>2</sup>

Concurrent with centrifugation, the AVN lesions were accessed sequentially. Using fluoroscopic guidance while carefully referencing preoperative 3D advanced imaging studies, Dr. Kamath malleted the decompression instruments through the cortex of the femur and tibia into the necrotic lesions. Power was not used to avoid heat necrosis. Intraoperative fluoroscopy in

*continued next page >*



Atul Kamath, MD  
kamatha@ccf.org  
216.445.7408

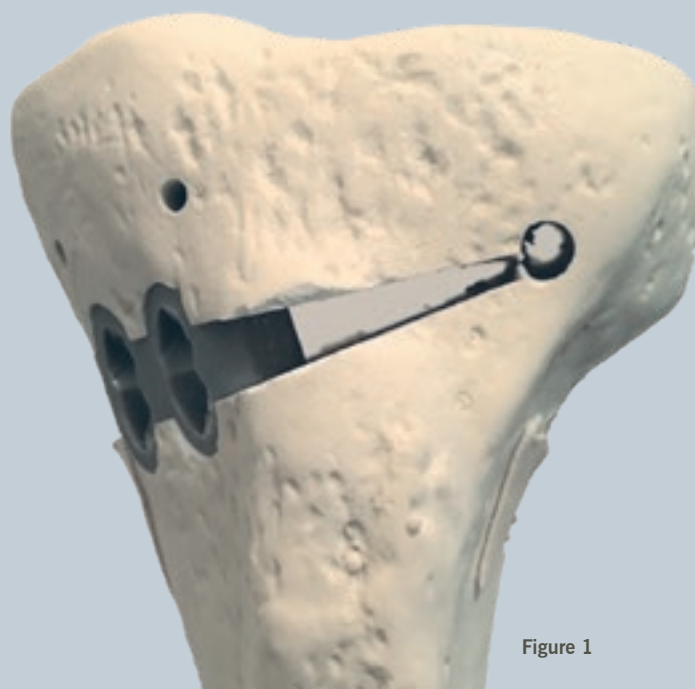


Figure 1



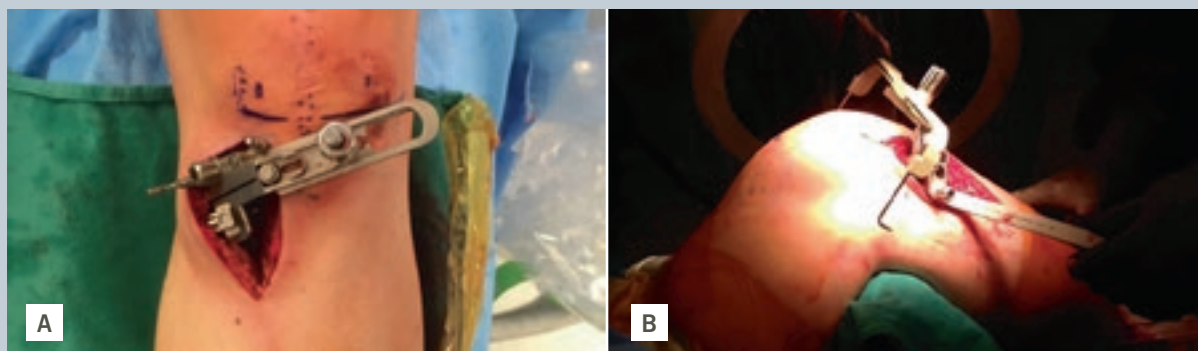


Figure 2

multiple planes demonstrated that the instruments were within the osteonecrotic lesion.

Next, the progenitor cells (bone marrow concentrate) were injected into the individual AVN sites. The coring instrument was removed, taking care to place some cancellous bone into the track. An SCP was performed on the left medial femoral condyle, with an injection of 3 cc of AccuFill® material via the trocar instrumentation. The patient tolerated the procedure without complication.

#### A remarkable road to recovery

The patient recovered remarkably well. Postoperative imaging demonstrated satisfactory healing and maintained limb alignment (Figures 3A, 3B). As soon as he completed his dedicated postoperative physical rehabilitation protocol after his most recent knee surgery, he began working with a personal trainer to prepare for an Ironman® event, which he would go on to complete less than one year later.

Given the complexity of his condition and the procedure, he will likely require a lifetime of follow-up care. His rehabilitation and athletic prowess are a testament to his psyche and motivation, which undoubtedly enabled him to maximize the benefits he received from his orthopaedic and biologic care at Cleveland Clinic.

#### Cleveland Clinic Hip Preservation Center

As a specialty center, the Hip Preservation Center treats many patients with rare conditions, like AVN, offering a diverse, multimodal approach to surgical and nonsurgical interventions. Its goal is to work with the patient to leverage advanced techniques to preserve damaged joints, rather than replace them, which was the approach in this particular case. This case harnessed both biologic and mechanical techniques to optimize the clinical result. Every patient is different, but in many cases, the longer a person's original joints can be maintained, the better — even if a replacement can be delayed for another five, 10 or 15 years.

The center is one of few in the United States that provides this level of comprehensive care for the hip/pelvis and entire lower extremity. Providers evaluate and treat patients of all ages for consultations and second opinions. Specialists and subspecialists from many areas work together as one unit and draw on a wide range of resources, from research to education to advanced diagnostics and procedural interventions. ■

*Dr. Kamath is a staff orthopaedic surgeon and Director of Cleveland Clinic's Hip Preservation Center*

#### References


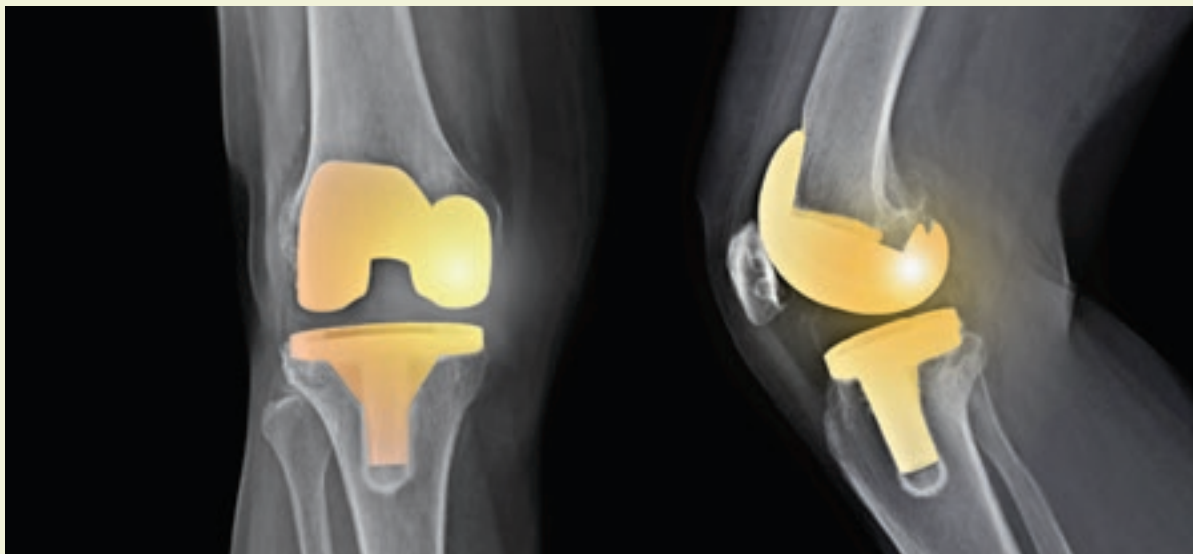
1. Moya-Angeler J, Gianakos AL, Villa JC, Ni A, Lane JM. Current concepts on osteonecrosis of the femoral head. *World J Orthop.* 2015;6(8):590-601. 2015 Sep 18.
2. Talathi NS, Kamath AF. Autologous stem cell implantation with core decompression for avascular necrosis of the femoral head. *J Clin Orthop Trauma.* 2018;9(4):349-352.

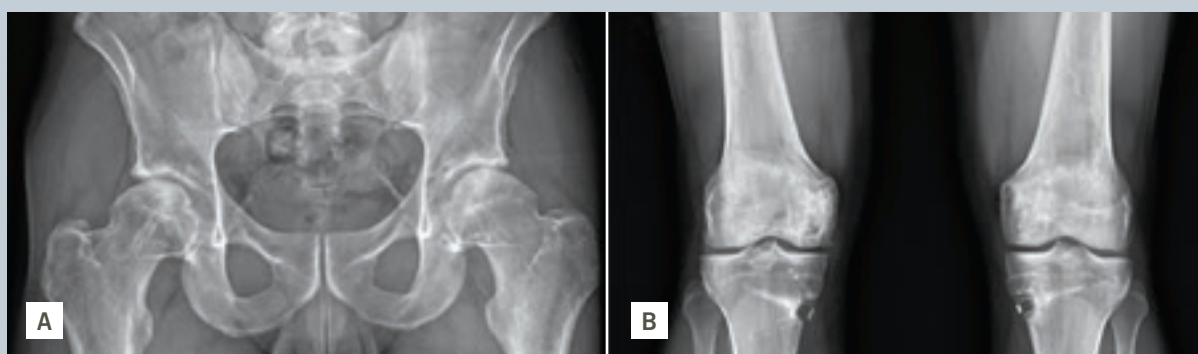


Figure 3

# PERSONALIZED OUTCOME PREDICTION OF PAIN AND FUNCTIONAL CHANGES FOLLOWING TOTAL KNEE ARTHROPLASTY

TKA OUTCOMES CALCULATOR TO HELP COUNSEL PATIENTS, MANAGE EXPECTATIONS



Alison K. Klika, MS  
klikaa@ccf.org  
216.444.4954



Nicolas S. Piuze, MD  
piuzzin@ccf.org  
216.445.9109

Total knee arthroplasty (TKA) has proved to be a safe, long-lasting solution to treat patients with knee joint disease. Despite the vast majority (90%) of patients reporting improvements in pain, function and quality of life, there are some patients who show no improvement or may even decline.<sup>1</sup>

Data suggest that up to 20% of patients express some level of dissatisfaction following TKA, commonly associated with reasons such as sociodemographic factors and baseline mental and physical health status.<sup>2</sup> Adverse events have been linked to patient-specific factors such as comorbidities and high BMI.<sup>3</sup>

## Leveraging a data-driven approach

Altogether, implementation of care pathways has focused on standardizing the way patients are optimized preoperatively for many of these risk factors in an effort to minimize postoperative complications and readmission.<sup>4</sup>

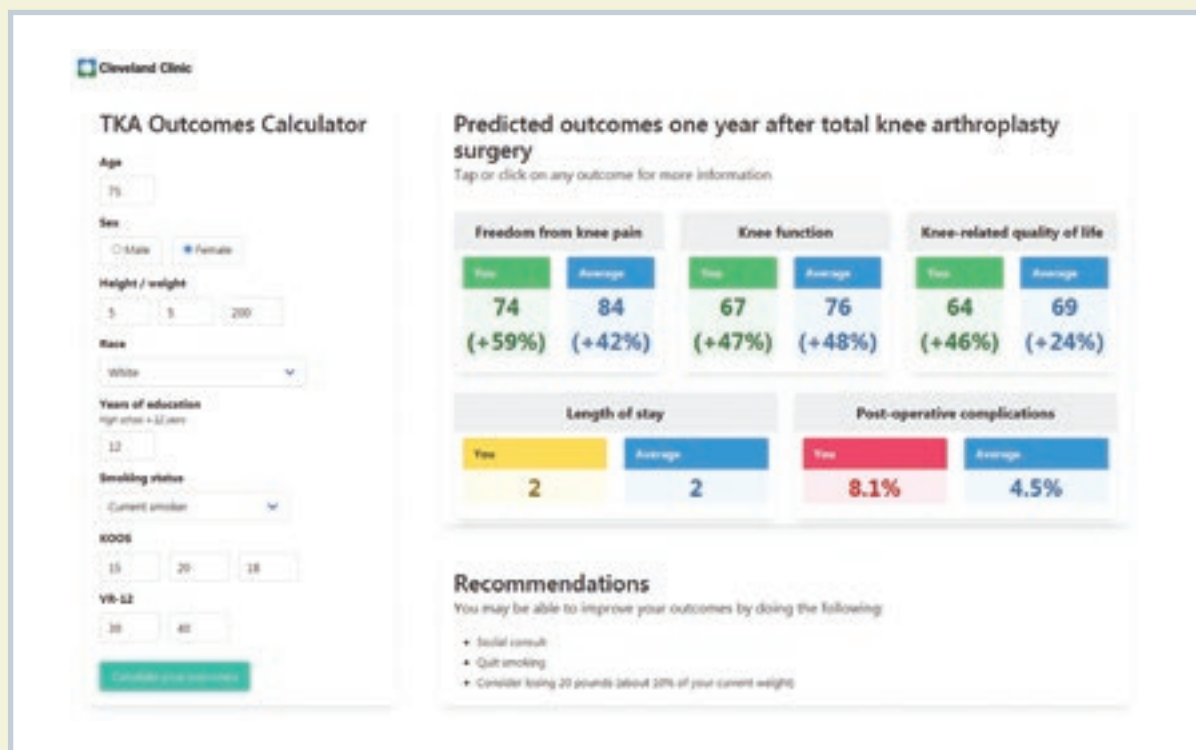
As personalized medicine continues to evolve and impact how we deliver care, a data-driven approach using predictive analytics to understand specifically how an individual may or may not benefit from TKA in terms of pain and function is valuable to the physician and the patient in the shared decision-making process. The ability to predict how changes to a modifiable factor (like BMI or smoking) may impact a patient's outcome facilitates these meaningful conversations.

Our adult reconstruction research team, with a multi-disciplinary composition of physicians, data analysts, statisticians and research professionals, has built a personalized outcome prediction tool for TKA patients to be administered preoperatively.<sup>5</sup> This effort utilized the Outcomes Management and Evaluation (OME) system, a prospective cohort database, to collect demographic and perioperative outcomes data (length of stay, readmission within 90 days). The team collected data on 5,958 TKA patients from July 2015 to June 2018 and patient-reported outcome measures (PROMs) at both baseline and one-year postoperatively on a subset of this cohort (N = 2,391). Specifically, these PROMs measured pain (Knee Injury and Osteoarthritis Outcome Score [KOOS] pain subscore), function (KOOS Physical Function Shortform [PS]) and quality of life (KOOS knee-related Quality of Life [QoL] subscore).

These data were used to construct regression models for each outcome, which were assessed for accuracy, cross-validated within the initial dataset, and again assessed for accuracy using a separate dataset from 3,750 TKA patients from July 2018 to June 2019 (one-year PROMs were collected from 2,095 TKA patients through June 2018 to allow for one-year outcomes).

*continued next page* ➤

**Figure 1.** Predicted outcomes calculator following total knee arthroplasty. The left panel shows the information that is input into the calculator; the right panel is the output information. The patient's predicted scores (+ or – improvement in parentheses) are shown alongside the “average” Cleveland Clinic patient scores (blue).



**Table 1.** Data show the area under the curve (AUC) accuracy measures for each model.

Outcome	AUC
Length of stay (days)	71.5
90-day readmission	65.0
1-yr KOOS pain	71.7
1-yr KOOS function	72.6
1-yr KOOS quality of life	70.5

### Using the TKA outcomes calculator

The models were programmed into an online calculator, as shown in Figure 1. This tool provides a visual display of the predicted outcomes of the patient's surgery, which is easily interpreted.

The patient's own outcomes are put into context by including benchmark achievements for the “typical” TKA patient. Additionally, suggestions for changes to modifiable factors can be made in real time to show the potential for improved outcomes to the patient.

We believe that using this tool to counsel patients and set accurate patient expectations for surgery will be highly valued by physicians and their patients and can positively impact patients' lives. It was our honor to receive the 2020 Current Concepts in Joint Replacement/

Orthopaedic Research and Education Foundation clinical practice award for this work.

Patients' scores are shown in one of three colors: green, yellow or red indicating, respectively, improvement, no change or decline. At the bottom are recommendations specific to the patient regarding his/her opportunity to modify factors that may improve outcomes. ■

*Dr. Piuze is a staff orthopaedic surgeon who serves as the Director of the Adult Reconstruction Research Team, with a focus on hip and knee replacements as well as orthobiologics and joint preservation.*

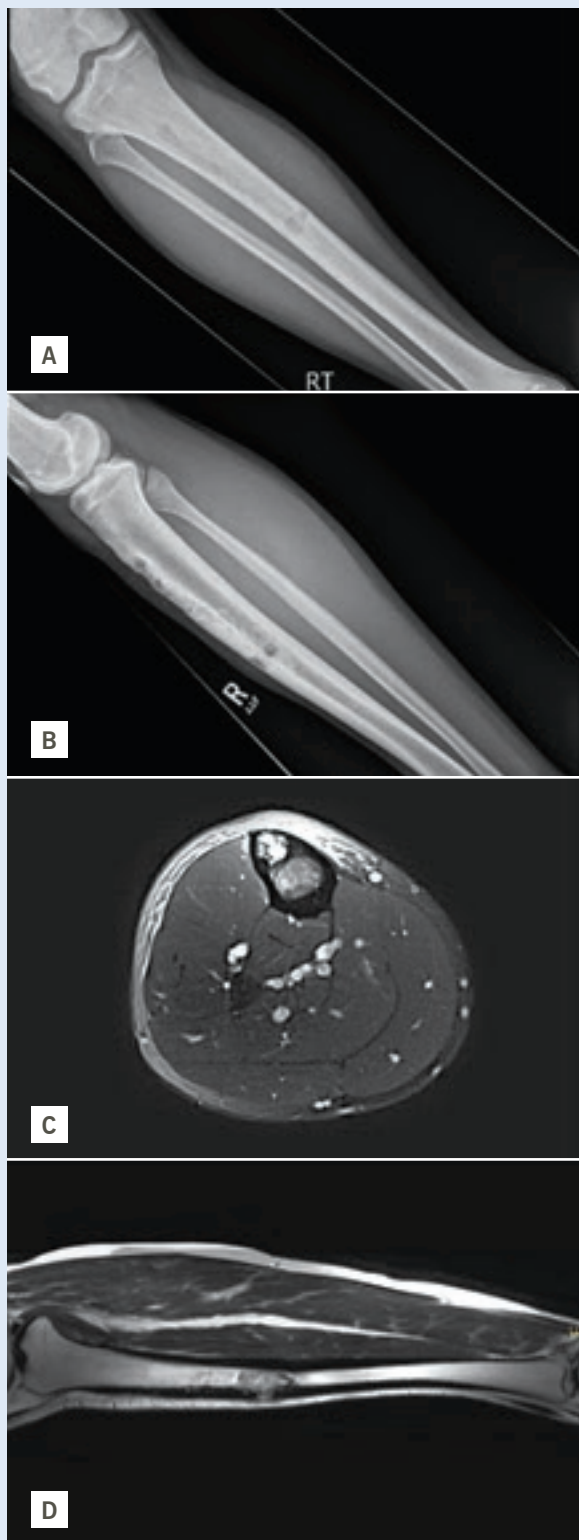
*Ms. Klika is the Research Program Manager for adult reconstruction in Ohio as well as orthopaedics in Cleveland Clinic Florida.*

*The authors acknowledge the following contributors to this work: Carlos Higuera, MD; Robert Molloy, MD; Kurt Spindler, MD; and Greg Strnad, MS.*

### References

1. NIH Consensus Statement of total knee replacement. NIH Consensus State Sci Statements 2003;20(1):1-34.
2. Gunaratne R, Pratt DN, Banda J, et al. Patient Dissatisfaction Following Total Knee Arthroplasty: A Systematic Review of the Literature. *J Arthroplasty*. 2017;32(12):3854-3860.
3. George J, Piuze NS, Ng M, et al. Association Between Body Mass Index and Thirty-Day Complications After Total Knee Arthroplasty. *J Arthroplasty*. 2018;33(3):865-871.
4. Featherall J, Brigati DP, Arney AN, et al. Effects of a Total Knee Arthroplasty Care Pathway on Cost, Quality, and Patient Experience: Toward Measuring the Triple Aim. *J Arthroplasty*. 2019;34(11):2561-2568.
5. Anis HK, Strnad GJ, Klika AK, et al. Developing a personalized outcome prediction tool for knee arthroplasty. *Bone Joint J*. 2020;102-B(9):1183-1193.

# BRIDGING THE GAP: SOLUTIONS FOR INTERCALARY LONG BONE RECONSTRUCTION



**Figure 1.** Patient is a 23-year-old with 12 months of tibial pain. AP and Lateral Radiographs (A, B) show a cortically based anterior tibial lesion, with axial (C) and coronal (D) MRI imaging suggesting cortical breakthrough and an aggressive marrow-replacing process.

## What are diaphyseal bone tumors?

Diaphyseal bone tumors present unique challenges in reconstruction. Compared to malignant and benign bone tumors close to a joint, diaphyseal bone tumors are rare. Tumors typically found in the diaphysis of long bones can be found in Table 1. Tumor histology patient age and comorbidity status, segment defect size, and patient prognosis all are important considerations when determining the appropriate type of reconstruction technique. Oftentimes, a multidisciplinary surgical team is required for reconstruction to address soft tissue coverage and revascularization concerns. Appropriate planning and a coordinated surgical effort are essential to a successful outcome.

## Case Study 1: Intercalary allograft reconstruction

A 23-year-old former Marine presented with one year of tibial pain that progressed to a point where he quit running. Imaging (Figure 1) suggested a diaphyseal tibial lesion. A core needle biopsy of the large lytic lesion suggested a classic type of adamantinoma. Systemic staging studies showed localized disease only.

A 17 cm segmental resection was performed with a proximal metaphysis junctional step cut. A bulk tibial allograft was fashioned to mirror the segmental defect, and the construct was dual plated. The plastic surgery team rotated a regional gastrocnemius flap over the diaphysis to aid with soft tissue coverage.

Eight months postop, the patient began having pain at the distal junction site. X-rays revealed a broken lateral plate and multiple broken screws (Figure 2). The proximal junction had healed uneventfully. He underwent a second operation to exchange hardware and graft the junction site with iliac crest autograft. His distal junction has gone on to union six months postop, and he is now four years out from his original tumor resection (Figure 3).

*continued next page >*



**Nathan Mesko, MD**  
meskon@ccf.org  
216.444.4603



**Lukas Nystrom, MD**  
nystrol@ccf.org  
216.445.7164

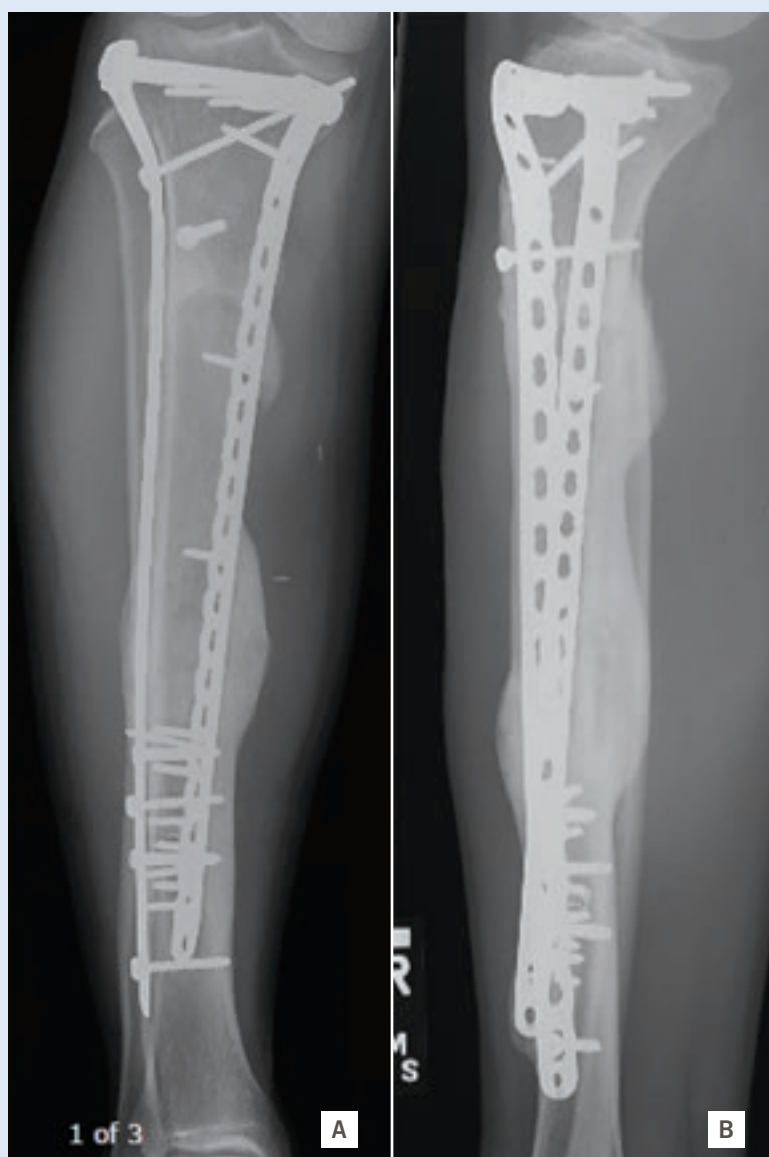
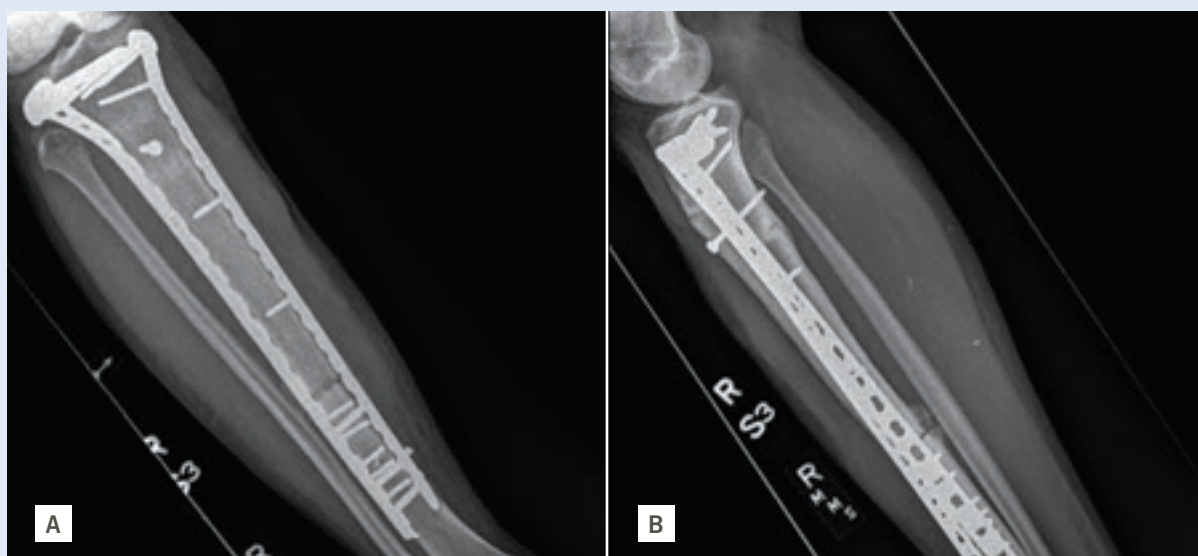
**Timothy Marks, MD**  
markst@ccf.org  
330.344.2663

TUMOR HISTOLOGY, PATIENT AGE AND COMORBIDITY STATUS, SEGMENT DEFECT SIZE AND PATIENT PROGNOSIS ALL ARE IMPORTANT CONSIDERATIONS WHEN DETERMINING THE APPROPRIATE TYPE OF RECONSTRUCTION TECHNIQUE.



**Figure 2.** AP and lateral (A, B) radiographs eight months postop of the right tibia, showing a healed proximal junction but a nonunion at the distal diaphyseal junction with broken screws noted.



**Figure 3.** AP and lateral (A, B) radiographs six months after the patient underwent nonunion surgery, with a plate revision and iliac crest bone grafting. The proximal and distal junctions have gone on to union, with no functional activity restriction.

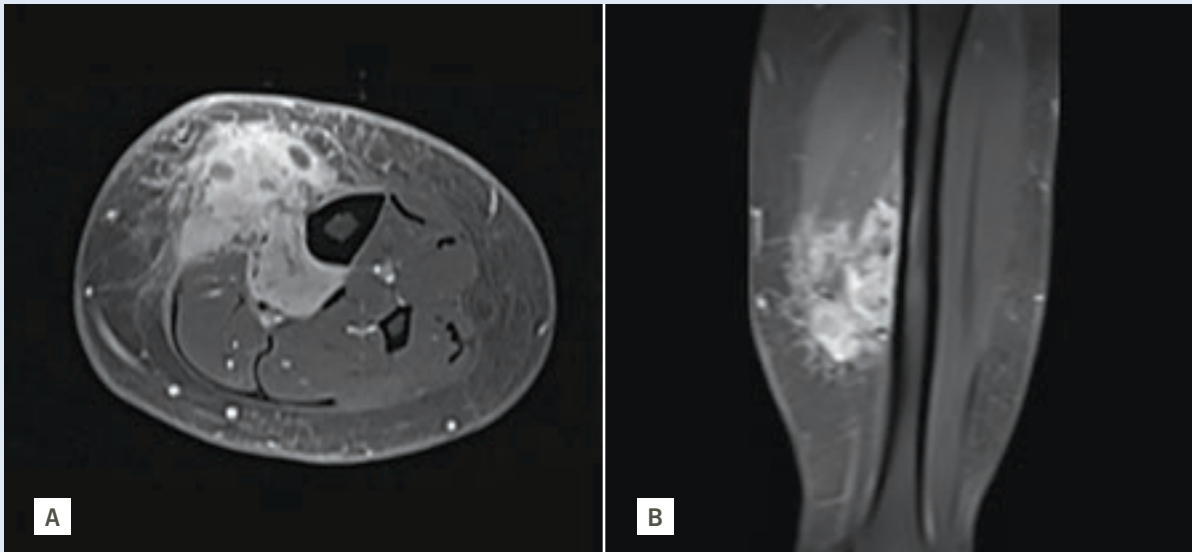
### Case Study 2: Intercalary segmental reconstruction

A 46-year-old school administrator presented with a distal tibial soft tissue mass, discovered during a routine primary care physician visit. Imaging suggested an aggressive soft tissue mass adjacent to the posterior tibial vessels and partially encasing the tibial diaphysis (Figure 4), while CT staging studies suggested an isolated 9 mm pleural-based mass. An image-guided biopsy revealed a high-grade dedifferentiated liposarcoma.

The patient underwent five weeks of preoperative radiotherapy. Restaging studies suggested a stable pleural-based mass. Multiple options for defect reconstruction were discussed, taking into account the patient's morbid obesity and the large soft tissue defect that would require a free soft tissue flap transfer.

The orthopaedic oncology, plastic surgery and vascular surgery teams coordinated to perform the surgery. A 9 cm intercalary tibial resection was made to facilitate a clean margin resection, along with sacrifice of the posterior tibial vessels (Figure 5). The tibial defect was then reconstructed with an intercalary endoprosthetic device with interlocking screws distal and proximal. The team performed a reverse saphenous vein graft bypass and then attached a contralateral free tensor fasciae latae flap for soft tissue coverage (Figure 6). The patient was restricted to toe-touch weight bearing for 12 weeks following surgery to allow for bony ingrowth of the prosthesis and soft tissue healing.





**Figure 4.** Post-contrast T1 axial (A) and coronal (B) MRI imaging shows a heterogeneously enhancing mass involving the superficial and deep posterior compartments with invasion through the investing calf fascia into the subcutaneous layer. The mass encircled more than 180 degrees of bone.

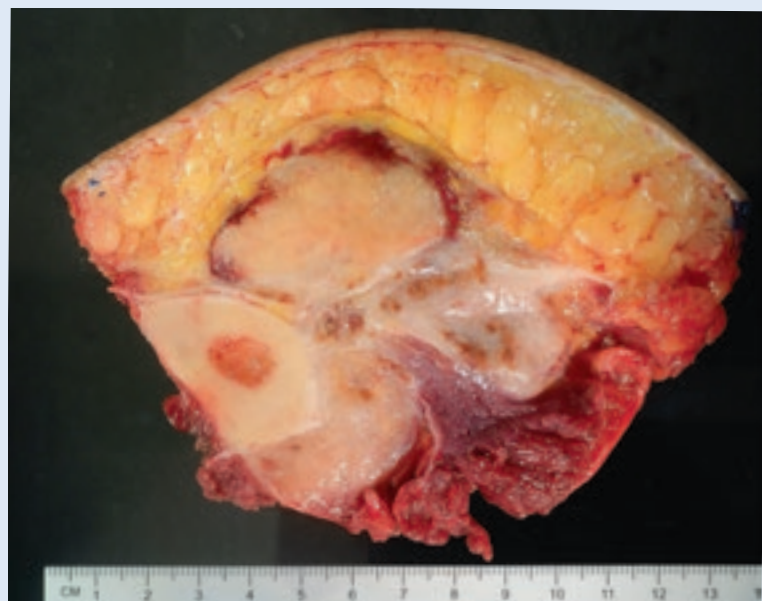### Many options exist

In young patients, biologic solutions can be ideal. While these solutions are often more complex and can prolong healing, the biologic bridging of bone provides a lower long-term complication risk profile. Fibular autograft, used by itself or to supplement a bulk allograft, is one option. Bone transport (distraction osteogenesis) is another option that provides a biologic solution for an intercalary defect. This can be done with an external fixation device over a transport intramedullary nail or with a combined plate and nail construct (plate-assist bone transport, PABST) (Figure 7).

Allograft is a standard option for defect reconstruction but comes with the potential for longer-term complications, such as allograft fracture, nonunion at the junction sites requiring regrafting surgery, graft resorption or infection. Likewise, an intercalary implant has potential loosening and infection complications, which may be avoided with newer-generation implants that allow for better fixation to the bone. Despite the potential complications, metal implants allow for more immediate weight-bearing and shorter intraoperative reconstruction times.

No one solution will work for every patient. A successful outcome hinges on informed decision-making that arises from the collaboration between the multidisciplinary team and the patient. Table 2 summarizes reconstruction techniques and their advantages/disadvantages.

*continued next page >*



**Figure 5.** Gross cross section of the resection specimen, showing the tumor surrounding the bone and invading both sides of the investing calf fascia.

**A**damantinoma / **A**denocarcinoma

**E**wings sarcoma / **E**osinophilic granuloma

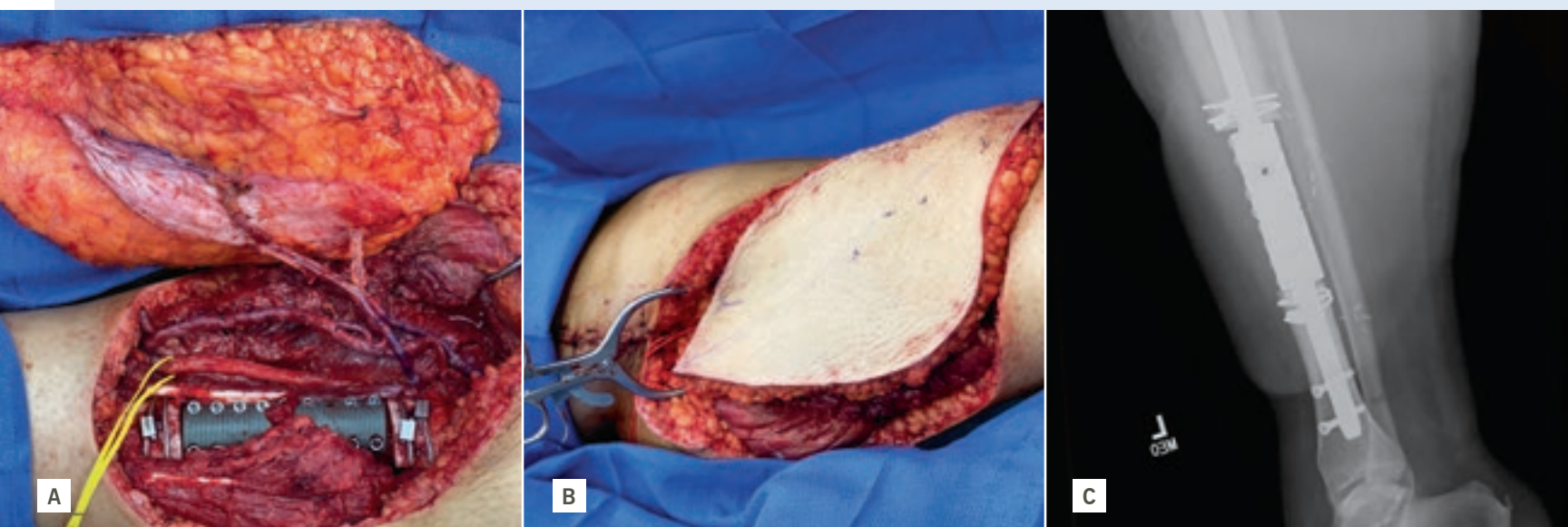**I**nfection

**O**steoid osteoma / **O**steoblastoma / **O**steofibrous dysplasia

Fibro**U**s dysplasia

**L**ymphoma / **m**Yeloma

**Table 1.** Differential diagnoses for diaphyseal bone tumors (using the mnemonic “AEIOU and Sometimes Y”)



**Figure 6.** A contralateral leg ALT flap was harvested and sewn into the posterior tibial vessel reverse saphenous vein bypass graft, to restore inflow and outflow to the flap (A). The 9 cm tibial defect was reconstructed using a press-fit intercalary tibial implant with interlocking screws proximal and distal. The final inset of the fasciocutaneous flap is pictured (B) along with a follow-up X-ray of the implant (C).

**Table 2.** Summary of Diaphyseal Bone Reconstruction Techniques

Segmental Reconstruction Technique Categories	Complications/Drawbacks	Advantages/Techniques
Autogenous Graft (i.e. Vascularized Fibula)	Donor site morbidity (i.e. foot drop)	Improved union rate
	Extended operative times, skilled microvascular surgeon required	Can be used combination with bulk allograft
		Fibula can hypertrophy and remodel
Allograft	Infection	Readily available
	Allograft Fracture, Nonunion, Resorption	Multiple fixation techniques allow for straight forward reconstruction
	Difficulty in matching size	Restores bone stock immediately
Intercalary Segmental Prosthesis	High risk of aseptic loosening	Cemented and press fit options available
	Infection	Modular device options allow for managing large range of defect sizes
	Metal artifact distortion on subsequent surveillance imaging	
Distraction Osteogenesis	Multiple pin site infections	Excellent “biologic” solution that is durable
	Prolonged treatment course, Multiple Operations	Callus/Regenerate formation occurs reliably even with cytotoxic therapy
	Technical Expertise, Detailed Pre-operative planning required	

EACH PATIENT DIAGNOSIS AND SCENARIO PRESENTS UNIQUE VARIABLES AND QUALITIES THAT REQUIRE A MULTIDISCIPLINARY SURGICAL AND CANCER TEAM TO WORK TOGETHER IN FORMULATING A SPECIFIC PLAN TAILORED TO EACH PATIENT.

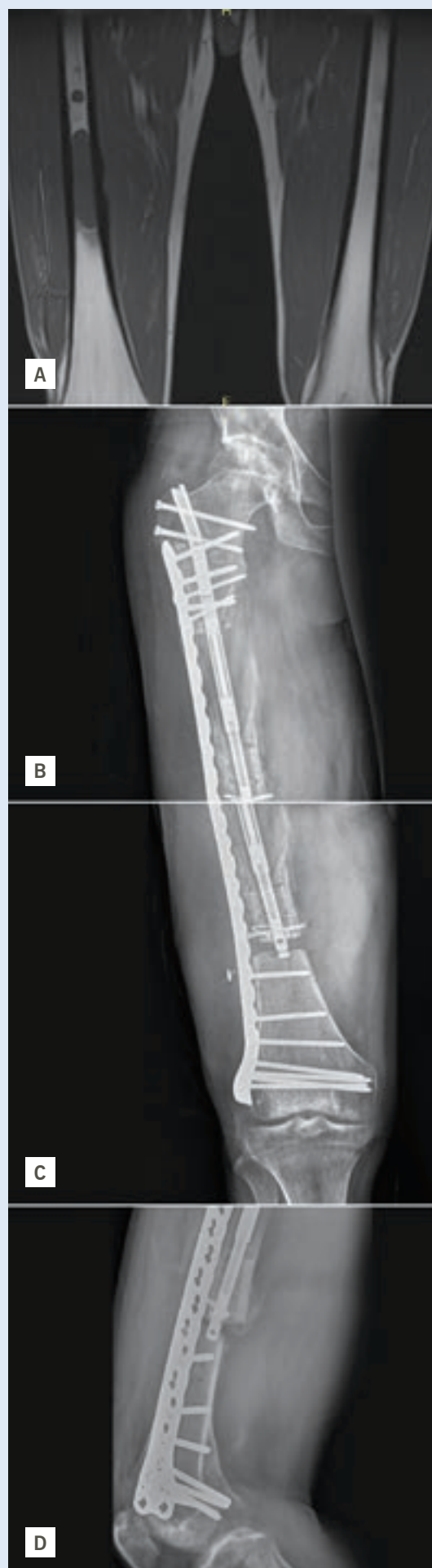**Each scenario is unique and requires creativity and partnership**

Each patient diagnosis and scenario presents unique variables and qualities that require a multidisciplinary surgical and cancer team to work together in formulating a specific plan tailored to each patient. Walking our patients through their surgical and surveillance journey while attempting to maintain maximum function with various reconstruction techniques is our top priority. ■

.....  
*Dr. Mesko is Director of the Musculoskeletal Tumor Center and Co-Director of the Sarcoma Program at Cleveland Clinic.*  
.....

*Dr. Nystrom is Co-Director of the Pediatric Sarcoma Program and Vice Chairman of Quality for the Orthopaedic & Rheumatologic Institute.*  
.....

*Dr. Marks is an orthopaedic oncologist with the Cleveland Clinic Akron General Orthopaedics Oncology team.*



**Figure 7.** Distraction osteogenesis, or bone transport, is an evolving technique that can use either external frame or a combined plate/nail construct, noninvasively lengthening the bone over a magnetized intramedullary nail device. Figure A shows a diaphyseal Ewing sarcoma with a skip metastasis that has undergone lengthening utilizing PABST to transport it across the defect and “dock” it at the distal junction (B-D).



# HOW MUSCULOSKELETAL VIRTUAL CARE IS DRIVING THE DIGITAL TRANSFORMATION OF ORTHOPAEDICS



**Dominic King, DO, FAOASM**  
kingd2@ccf.org  
216.444.2094



**Jonathan L. Schaffer, MD, MBA**  
schaffj@ccf.org  
216.444.8960

The COVID-19 pandemic compelled us to think differently about the way patients access orthopaedic care and the ways in which we deliver that care. However, even prior to the pandemic, our team recognized that digital transformation must encompass several critical and emerging issues related to orthopaedic access, triage, treatment, education and retention.

Central to our efforts, the Orthopaedic Informatics Working Group (OIWG) was formed as a collaborative effort to ensure that all the appropriate department stakeholder groups, including clinical subspecialty and administrative support teams, are represented. Our team recently published a framework for the responsible integration of musculoskeletal virtual care (MSKVC) in orthopaedic surgery.<sup>1</sup>

## The opportunities and challenges of musculoskeletal virtual care

The demand for MSKVC is projected to substantially increase during and beyond the COVID-19 crisis. This is an opportunity to improve access for patients on a lower-cost platform while providing equivalent — or improved — safety and patient satisfaction as compared with the traditional face-to-face model of outpatient care.

Incorporating MSKVC into all aspects of the delivery of care continuum is the challenge, and our teams are addressing this in all episodes of care. The ability to adapt to a new model will be essential for musculoskeletal clinical teams as well as organizations as established paradigms are shaken from their foundation and transformed.

## Our strategy for integration

OIWG has developed a strategy for integrating MSKVC as an underlying theme across all new innovations involving the clinical transformation of our department. The following overview highlights several MSKVC, Orthopaedic Informatics and Clinical Transformation projects to optimize and enhance access to and delivery of the care we provide in the Department of Orthopaedic Surgery.

The OIWG is always soliciting ideas for opportunities to improve the orthopaedic episode of care. We are eager to continue integrating this initiative into our platform with the goal of providing the highest quality of care to our patients. ■

---

*Dr. King is a sports medicine physician in the Department of Orthopaedic Surgery, Manager of Orthopaedic Informatics and Director of Orthopaedic & Rheumatologic Institute Clinical Transformation.*

---

*Dr. Schaffer is an adult reconstructive surgeon specializing in knee arthroplasty in the Department of Orthopaedic Surgery and Program Director for the Global MedAssist Program in International Operations.*

---

## Reference

King D, Emara AK, Ng MK, Evans PJ, Estes K, Spindler KP, Mroz T, Patterson BM, Krebs VE, Pinney S, Piuze NS, Schaffer, JL. Transformation from a traditional model to a virtual model of care in orthopaedic surgery: COVID-19 experience and beyond. *Bone & Joint Open*, 2020;1(6):272-280.



## Find the Care You Need

Use this pediatric fractures assessment tool to help schedule an appointment or virtual visit with our Pediatric Orthopaedic team.

Scan this code with the camera app on your phone/tablet.

Web Scheduling Triage and Access Tool (WebSTAT)	<ul style="list-style-type: none"> <li>› Online patient (or parent) self-scheduling for an in-person or virtual visit with the most appropriate provider.</li> <li>› Virtual visit and in-person scheduling are live for pediatric fractures (<a href="https://clevelandclinic.org/pediatricfracture">clevelandclinic.org/pediatricfracture</a>) or care with our Pediatric Orthopaedics surgery team.</li> </ul>
Musculoskeletal Virtual Triage Channel (MSK VTC)	<ul style="list-style-type: none"> <li>› Live, interprofessional triage for our primary care community.</li> <li>› Orthopaedic clinical and administrative support ensures that patient appointments are made in real time, some even for the same day, providing a higher level of service and an opportunity to improve patient satisfaction.</li> <li>› Staffed from the start of the clinical day until the early evening to provide services when needed by referring clinicians.</li> </ul>
Physical exam documentation templates	<ul style="list-style-type: none"> <li>› Transformational shift in the way we collect physical examination data in our notes while also creating a data collection system for outcomes studies.</li> <li>› Ability to create macros for physical examinations, both in-person and virtual.</li> </ul>
Orthopaedic appointment	<ul style="list-style-type: none"> <li>› Ability for patients to automatically be offered sooner appointments directly through our patient portal with no human interaction.</li> </ul>
Communication tools	<ul style="list-style-type: none"> <li>› One repository for all departmental clinical operations information. Informatics updates; leadership and educational podcasts and staff meeting video links; newsletters; and research, marketing and communications, and quality updates.</li> </ul>
TKA/THA care path transformation	<ul style="list-style-type: none"> <li>› A foundational technologic overhaul for the provider and patient with episode-of-care management documentation tools.</li> <li>› Centralization of technologies, from patient-entered data at specific points of the care process to provider and wearable data streams. Most important, specific events can be automatically monitored to ensure completion at the appropriate time and help to complete assessments for patients scheduled for operative intervention.</li> </ul>
Governance	<ul style="list-style-type: none"> <li>› As many of these efforts require coordination with our information technology colleagues who manage the enterprise electronic medical record and associated systems, alignment is key. The OIWG has been charged by departmental leadership with providing the internal coordination and management of the many varied requests to ensure optimal completion of the highest-impact projects.</li> </ul>

THE ABILITY TO ADAPT TO A NEW MODEL WILL BE ESSENTIAL FOR MUSCULOSKELETAL CLINICAL TEAMS AS WELL AS ORGANIZATIONS, AS ESTABLISHED PARADIGMS ARE SHAKEN FROM THEIR FOUNDATION AND TRANSFORMED.



# IDENTIFYING THE PATIENT, DISEASE, SURGICAL AND IMPLANT POSITIONAL FACTORS THAT PREDICT OUTCOMES FOLLOWING TOTAL SHOULDER ARTHROPLASTY



**Eric T. Ricchetti, MD**  
richee@ccf.org  
216.445.6915



**Kathleen A. Derwin, PhD**  
derwink@ccf.org  
216.445.5982



**Joseph P. Iannotti, MD, PhD**  
iannotj@ccf.org  
954.659.6538

The number of shoulder arthroplasty procedures performed in the United States continues to rise, with current estimates ranging from 55,000 to 80,000 per year and increases of 300% or more expected in the coming years. While total shoulder arthroplasty (TSA) is the preferred surgical treatment for advanced glenohumeral arthritis, a subset of patients either do not experience clinical improvement or sustain a complication. Glenoid component loosening is reported as the most common long-term complication of anatomic TSA and a common reason for revision surgery.

In addition, the factors associated with poor short- and long-term clinical outcomes after anatomic TSA are still not well understood, in part due to the lack of large prospective cohort studies allowing for multivariable analysis. Furthermore, while an association between glenoid component loosening on plain radiographs and worse clinical outcomes, including the need for revision surgery, has been shown at longer follow-up, the significance of early radiographic changes on longer-term clinical outcomes has not been established, nor have the factors associated with glenoid component loosening been well defined. The ability to reliably and accurately measure subtle radiographic factors longitudinally following anatomic TSA may allow for a deeper understanding of the relationship between short- and longer-term clinical outcomes.

## Assessing TSA outcomes

The objective of our recently funded National Institutes of Health R01 grant is to identify the factors associated with short- and longer-term clinical and radiographic outcomes following anatomic TSA by utilizing two unique and ongoing prospective TSA cohorts: a larger cohort (over 1,200 projected cases) collecting baseline demographic, disease-related and surgical factors together with one-year clinical outcomes, and a smaller cohort (N = 152) collecting CT imaging-based measures as well as minimum five-year clinical outcomes. The central hypothesis is that short-term (one-year)

outcomes will associate with certain demographic, disease-related and surgical factors, while longer-term (minimum five years) outcomes will associate with the factors influencing short-term outcomes as well as radiographic changes that may be clinically silent in the short term, in particular glenoid component shift and central anchor peg osteolysis at a minimum two-year follow-up.

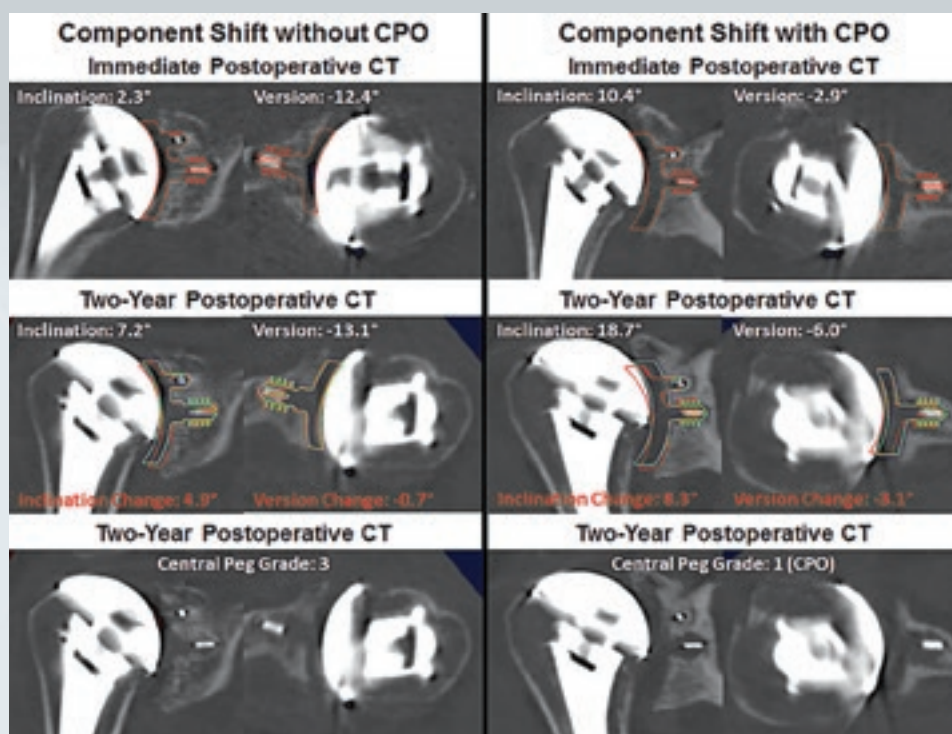
## Leveraging the Outcomes Management and Evaluation system

An innovation in this grant is the ability to investigate a large prospective cohort of patients undergoing primary anatomic TSA for glenohumeral osteoarthritis with multivariable analysis through the Outcomes Management and Evaluation (OME) system at Cleveland Clinic. OME provides a valid, scalable, cost-effective and prospective data collection tool for assessment of clinical outcomes with a high rate of postoperative follow-up.<sup>1</sup> OME will be used to assess the extent to which 20 baseline demographic, disease-related and surgical factors are associated with patient-reported outcomes at one-year postoperatively. We hypothesize that certain factors will independently associate with one-year patient-reported outcomes (Penn Shoulder Score [PSS], Single Assessment Numeric Evaluation score [SANE]), after controlling for the other factors, and develop predictive models for these one-year clinical outcomes.

## Novel use of 3D imaging

Another innovation is the use of previously validated novel methods of 3D imaging analysis using widely accessible CT scanning together with metal artifact reduction (MAR) techniques that allow for reliable and accurate determination of implant position of a polyethylene glenoid component following TSA, with the ability to detect subtle changes in both over time.<sup>2-6</sup> These methods enable the assessment of preoperative bony pathology and postoperative implant position, as well as provide detailed information about other structures, including the rotator cuff and bone-implant interface, which may contribute to implant longevity and clinical outcomes.





**Figure:** Examples of shift of the glenoid component on 3D CT imaging analysis, without (left panel) and with (right panel) central peg osteolysis (CPO). In both examples, digital templates of the glenoid and humeral head component positions from an immediate postoperative CT (red templates) and a minimum two-year follow-up CT (green templates) are superimposed on representative coronal or axial images from the postoperative CT scans. In the panel on the left, a patient with an A2 glenoid had placement of a standard glenoid component, with the immediate postoperative CT showing the glenoid component in 2.3° of inclination and -12.4° of version (top row). On the minimum 2 year follow-up CT, the glenoid component was in 7.2° of inclination and -13.1° of version, representing a change in glenoid component position of 4.9° of inclination and -0.7° of version (middle row). The digital templates from both time points are overlaid on the minimum two-year follow-up CT images in the middle row to demonstrate the glenoid component shift into increased inclination. A central anchor peg grade of 3 is seen on the minimum two-year follow-up CT with the digital templates removed (bottom row). In the panel on the right, a patient with a B3 glenoid had placement of an augmented glenoid component, with the immediate postoperative CT showing the glenoid component in 10.4° of inclination and -2.9° of version (top row). On the minimum two-year follow-up CT, the glenoid component was in 18.7° of inclination and -6.0° of version, representing a change in glenoid component position of 8.3° of inclination and -3.1° of version (middle row). The digital templates from both time points are overlaid on the minimum two-year follow-up CT images in the middle row to demonstrate the glenoid component shift into both increased inclination and increased retroversion. A central anchor peg grade of 1 is seen on the minimum two-year follow-up CT with the digital templates removed, indicating CPO (bottom row).

Our unique cohort of 152 anatomic TSA patients has been followed with sequential 3D CT imaging analysis to two years postoperatively. This cohort will allow investigation of whether early evidence of glenoid component shift, which cannot be detected by standard X-rays, will predict later, more obvious component loosening and/or premature clinical failure seen at a minimum of five years after surgery. We will conduct analyses of the incremental contribution of CT imaging-based radiologic factors to the prediction of longer-term clinical outcomes at a minimum of five years after primary anatomic TSA, including glenoid component shift and central peg osteolysis, beyond that provided by the perioperative risk factors identified in the larger OME cohort.

### Clinical implications for TSA patients

We expect to address gaps in prior literature by utilizing these two unique prospective anatomic TSA cohorts to simultaneously investigate the factors that associate with short- and longer-term clinical outcomes following anatomic TSA. Identifying risk factors that are important to clinical outcomes would allow for the design of future prospective clinical trial(s) to investigate modification of these factors either directly or indirectly through preoperative intervention or modification of surgical treatments and/or patient selection based on these factors, with the aim of improving outcomes and survivorship following anatomic TSA. ■

*Dr. Ricchetti is a staff orthopaedic surgeon and Center Director for Shoulder Surgery in the Department of Orthopaedic Surgery. Dr. Derwin is staff at the Lerner Research Institute and Director of the Cleveland Clinic Musculoskeletal Research Center. Dr. Iannotti is Chief of Staff of Cleveland Clinic Florida.*

### References

1. Cleveland O, Piuze NS, Strnad G, et al. Implementing a Scientifically Valid, Cost-Effective, and Scalable Data Collection System at Point of Care: The Cleveland Clinic OME Cohort. *J Bone Joint Surg Am.* 2019;101(5):458-464.
2. Ricchetti ET, Jun BJ, Cain RA, Youderian A, Rodriguez EJ, Kusin D, Subhas N, Patterson TE, Iannotti JP. Sequential 3-dimensional computed tomography analysis of implant position following total shoulder arthroplasty. *J Shoulder Elbow Surg.* 2018 Feb 7. Epub 2018/02/11.
3. Iannotti JP, Ricchetti ET, Rodriguez EJ, Bryan JA. Development and validation of a new method of 3-dimensional assessment of glenoid and humeral component position after total shoulder arthroplasty. *J Shoulder Elbow Surg.* Oct;22(10):1413-22. Epub Feb. 11, 2018.
4. Iannotti JP, Walker K, Rodriguez E, Patterson TE, Jun BJ, Ricchetti ET. Accuracy of 3-Dimensional Planning, Implant Templating, and Patient-Specific Instrumentation in Anatomic Total Shoulder Arthroplasty. *J Bone Joint Surg Am.* 2019;101(5):446-457.
5. Iannotti JP, Weiner S, Rodriguez E, Subhas N, Patterson TE, Jun BJ, Ricchetti ET. Three-dimensional imaging and templating improve glenoid implant positioning. *J Bone Joint Surg Am.* 2015;97(8):651-658.
6. Ricchetti ET, Jun BJ, Jin Y, Entezari V, Patterson TE, Derwin KA, Iannotti JP. Three-Dimensional Computed Tomography Analysis of Pathologic Correction in Total Shoulder Arthroplasty Based on Severity of Preoperative Pathology. *J Shoulder Elbow Surg.* 2020 Aug 7;S1058-2746(20)30628-5. doi: 10.1016/j.jse.2020.07.033. Online ahead of print.



The Cleveland Clinic Foundation  
9500 Euclid Ave. | AC311  
Cleveland, OH 44195



# ORTHOPAEDIC INSIGHTS

WINTER 2021

## 24/7 Referrals

**855.REFER.123** (855.733.3712)  
**[clevelandclinic.org/refer123](https://clevelandclinic.org/refer123)**

### OUTCOMES DATA

View Outcomes books at  
**[clevelandclinic.org/outcomes](https://clevelandclinic.org/outcomes)**

### CME OPPORTUNITIES

Visit **[ccfcme.org](https://ccfcme.org)** for live and online offerings from  
Cleveland Clinic's Center for Continuing Education.

## Stay Connected with Cleveland Clinic's Orthopaedic & Rheumatologic Institute

### CONSULT QD—ORTHOPAEDICS

News, research and perspectives from Cleveland Clinic experts.  
**[consultqd.clevelandclinic.org/topics/orthopaedics](https://consultqd.clevelandclinic.org/topics/orthopaedics)**



**[Facebook.com/CMECLlevelandClinic](https://Facebook.com/CMECLlevelandClinic)**



**[@CleClinicMD](https://twitter.com/CleClinicMD)**



**[clevelandclinic.org/MDlinkedin](https://clevelandclinic.org/MDlinkedin)**



**[clevelandclinic.org/ortho](https://clevelandclinic.org/ortho)**



**Every life deserves world class care.**

9500 Euclid Ave., Cleveland, OH 44195

The Orthopaedic & Rheumatologic Institute brings together physicians, researchers and engineers to pursue excellence and innovation in the care of patients with joint, bone, muscle, connective tissue and immune disorders. The Orthopaedic & Rheumatologic Institute is one of 26 clinical and special expertise institutes at Cleveland Clinic, a nonprofit academic medical center ranked as one of the nation's top hospitals by *U.S. News & World Report*, where more than 3,900 staff physicians and researchers in 180 specialties collaborate to give every patient the best outcome and experience.  
[clevelandclinic.org](https://clevelandclinic.org)

©2020 The Cleveland Clinic Foundation