



# ORTHOPAEDIC INSIGHTS

SUMMER 2019

A PHYSICIAN NEWSLETTER FROM  
THE DEPARTMENT OF ORTHOPAEDIC SURGERY

## IN THIS ISSUE

- 3** Magnetic Rods for Preoperative Skeletal Traction in Adolescent Idiopathic Scoliosis
- 5** Primary vs. Staged Reconstruction After Soft Tissue Sarcoma Excision
- 7** Procedure Preserves Hip in Young Adult with Perthes Disease
- 9** 3D Imaging Analysis May Predict Risk of Post-Traumatic Osteoarthritis Following ACL Repair
- 11** Artificial Intelligence Accurately Predicts the Orthopaedic Episode of Care
- 12** Degree of Obesity Relates to Risk of Postoperative Complications in Hip and Knee Arthroplasty
- 14** Orthobiologics Update: The Search for Reproducible Evidence Continues
- 16** 3D Planning, Implant Templating and Patient-Specific Instrumentation in Anatomic Total Shoulder Arthroplasty

# DEAR COLLEAGUES



I am honored to present this issue of *Orthopaedic Insights*, which spotlights the efforts of physicians and researchers from Cleveland Clinic's Department of Orthopaedic Surgery, who collaborate to find innovative, multidisciplinary solutions for our

patients. We preserve joints; we relieve pain; we offer hope. This is the heart of our mission: putting patients first, and pioneering innovative techniques and technologies to treat their injury or disease. You'll see many examples of such innovations in this issue, including:

- Our cover story on the use of magnetic rods to provide preoperative skeletal traction in a 14-year-old with adolescent idiopathic scoliosis (p. 3).
- A comparison of primary and staged reconstruction after soft tissue sarcoma excision (p. 5).
- A surgical technique that preserved the hip of a 28-year-old with Perthes disease (p. 7).
- An overview of a study of early bone-shape changes following ACL repair, as measured by comprehensive 3D imaging, which may predict risk of developing post-traumatic osteoarthritis (p. 9).
- A resident-authored article on the application of artificial intelligence to predict the orthopaedic episode of care (p. 11).
- An analysis of the relationship between obesity and outcomes in hip and knee arthroplasty (p. 12).
- A review of recent research related to the efficacy of orthobiologics in relieving symptoms of knee osteoarthritis (p. 14).

**Subscribe to *Orthopaedic Insights* eNews to learn about the latest innovations, research and educational programs from Cleveland Clinic: [clevelandclinic.org/orthoinsights](http://clevelandclinic.org/orthoinsights).**

- A comprehensive look at 3D planning, implant templating and patient-specific instrumentation in total shoulder arthroplasty (p. 16).

Thank you for taking the time to review these articles, which represent the tremendous work of our staff and are just a sampling of the innovative clinical care and research programs our team undertakes.

We look forward to continued collaboration with you, our valued colleagues. I encourage your questions and comments.

Respectfully,

BRENDAN M. PATTERSON, MD

Chairman, Orthopaedic Surgery  
Interim Chair, Orthopaedic & Rheumatologic Institute

216.445.4792 | [patterb2@ccf.org](mailto:patterb2@ccf.org)

---

## ORTHOPAEDIC INSIGHTS™ | SUMMER 2019

*Orthopaedic Insights* is published by Cleveland Clinic's Department of Orthopaedic Surgery to inform musculoskeletal specialists about advances in diagnosis, medical and surgical management, and research.

**Brendan M. Patterson, MD**  
Chairman, Department of Orthopaedic Surgery

**Jennifer Lonzer**, Managing Editor

**Michael Viars**, Art Director

**Stephen Travarca**, Photography (Cover)

**Beth Lukco**, Marketing Manager

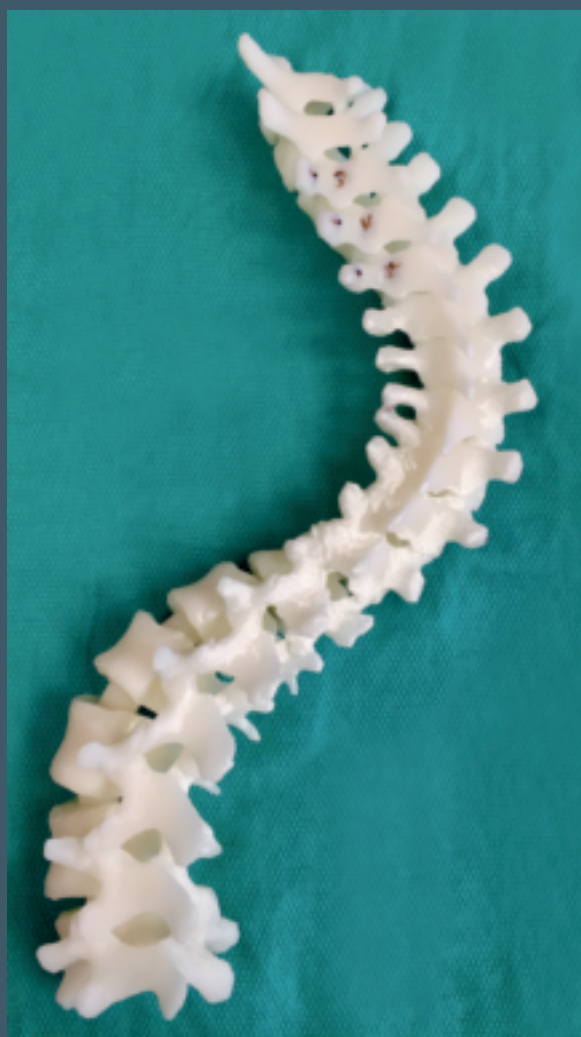*Orthopaedic Insights* is written for physicians and should be relied on for medical education purposes only. It does not provide a complete overview of the topics covered and should not replace a physician's independent judgment about the appropriateness or risks of a procedure for a given patient.

© 2019 The Cleveland Clinic Foundation

# MAGNETIC RODS FOR PREOPERATIVE SKELETAL TRACTION IN ADOLESCENT IDIOPATHIC SCOLIOSIS: A CASE STUDY

Skeletal traction is a useful and time-tested preoperative treatment for children and adolescents with severe scoliosis. Studies demonstrate that it can improve curve flexibility and subsequently help achieve optimal curve correction during spinal fusion. However, traction setups are bulky, uncomfortable and significantly restrict mobility. Consequently, they are extremely unpopular with patients and their families.

In the following case study, an external, magnetically driven distraction rod system that came onto the market five years ago provided an alternative way to enhance curve flexibility without the use of skeletal traction in an adolescent scoliosis patient.



To facilitate operative planning and intraoperative decision-making, a life-size model of the thoracic and lumbar spine was printed, then sterilized, for examination as needed during the procedure.



Intraoperative photograph of the final construct; note the hybrid fixation of hooks, sublaminar nylon bands and pedicle screws.

The NuVasive MAGEC® (MAGnetic Expansion Control) system, comprising magnetic spinal rods and a hand-held external remote controller, was cleared by the FDA in 2014 for treatment of young patients with severe progressive spinal deformities who are at risk of developing thoracic insufficiency syndrome. It is commonly used as a less-invasive alternative to traditional growing rods, which can minimize the progression of scoliosis in young patients for whom bracing is not appropriate or unlikely to be tolerated. However, instead of requiring repeated surgeries every six months for manual distraction, the magnetic rods can be lengthened, using an external magnet system, during a short in-office procedure every three months. Lengthenings can be tailored to the patient and are typically 3 to 6 mm at a time.

A Cleveland Clinic patient with severe adolescent idiopathic scoliosis was among the first U.S. patients for whom the device was used for internal traction as part of a staged procedure.



Thomas E. Kuivila, MD  
kuivilt@ccf.org  
216.444.2741

*continued next page >*

OVER THE COURSE OF THREE MONTHS, THE PATIENT ACHIEVED MARKED IMPROVEMENT IN CURVATURE AND FLEXIBILITY AND DID NOT COMPLAIN OF PAIN FROM THE DISTRACTION PROCEDURE.

### Case presentation

A 14-year-old girl presented at Cleveland Clinic with advanced, severe adolescent idiopathic scoliosis of the thoracolumbar region. Radiographs revealed a thoracic and lumbar curve in excess of 90 degrees with an axial rotation in excess of 70 degrees. An Adams forward bend test showed a dramatic and severe R rib prominence and markedly abnormal waist and shoulder asymmetry.

The patient rated her back discomfort at 7 on a scale from 1 to 10, with increasing pain when sitting for more than 30 minutes and during activity.

After discussing in detail the options for treatment with the patient and her family, they agreed to magnetic rod placement and weekly distraction for eight to 12 weeks, followed by a formal spinal fusion.

### Placing the rods

During the initial surgery, a magnetic rod was placed on either side of the spine, with screws placed bilaterally in L3 and L4 and hooks placed at T3, T4 and T5 on the left side and T9 and T10 on the right. The curve was markedly stiff, and paraspinal musculature was tight.

An innovative aspect of the procedure was the addition of a life-size 3D printed model of the spinal column based on a high-resolution CT scan of the patient. In preoperative planning, this model was useful in helping the surgical team get a sense of the anatomy of the complex rotational deformity as well as pedicle size and orientation. The 3D model was useful during the procedure to help ensure that screws were placed accurately.

### Follow-up

After surgery, weekly distractions of the rods were performed on the patient in the office setting. The titanium rods have an internal magnet that is activated by an external device placed against the child's bare back. Powerful magnets within the device cause the magnet in the rod to rotate, and thus the rod is slowly and accurately lengthened.

Over the course of three months, the patient achieved marked improvement in curvature and flexibility and did not complain of pain from the distraction procedure.

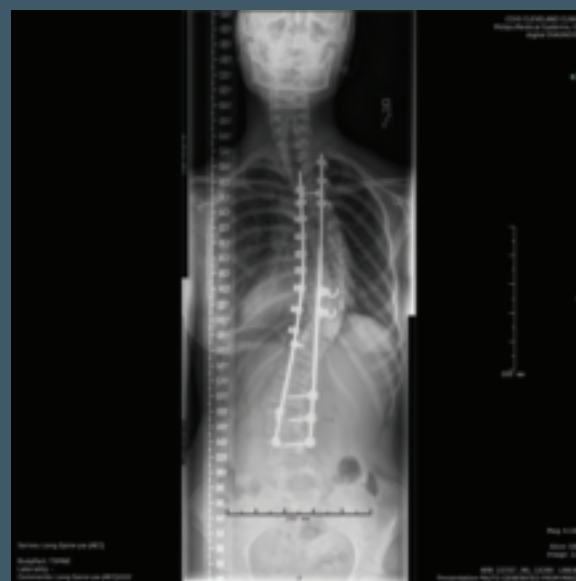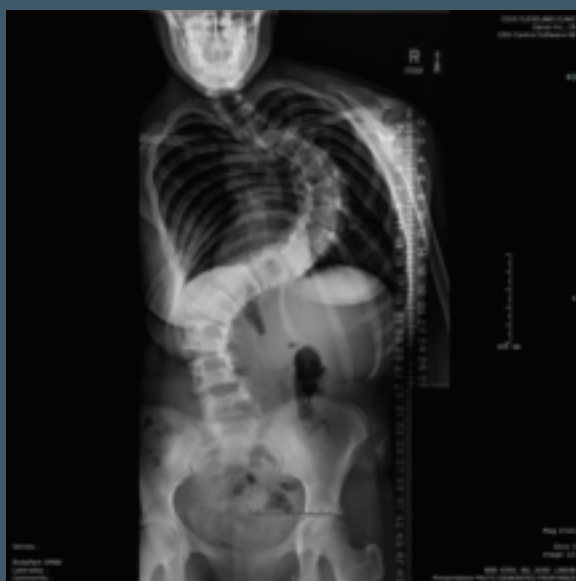### Removal and outlook

Three months after implantation, the magnetic growing rods were surgically removed, and new permanent, segmental spinal instrumentation was placed along with graft material to achieve spinal fusion.

Now, at nine months postop, the patient is doing well. She is back in school full time and living pain-free, with a new outlook on life owing to a dramatically improved alignment.

This device appears to be a promising, less invasive alternative to preoperative skeletal traction, with reduced pain and immobility for the patient. European studies demonstrate and endorse the use of magnetic rods as another tool for the management of advanced spinal deformity. ■

**Thomas Kuivila, MD**, is a Staff physician in Pediatric Orthopaedic Surgery, Vice Chair for Education in the Orthopaedic & Rheumatologic Institute, and Residency Program Director in Orthopaedic Surgery.



X-rays show the curvature of the patient's spine before implantation of the magnetic rods and seven months after spinal fusion and placement of permanent rods.



# SIMILAR OUTCOMES ACHIEVED IN PRIMARY VS. STAGED RECONSTRUCTION AFTER SOFT TISSUE SARCOMA EXCISION

The primary treatment for soft tissue sarcoma (STS) is surgical resection of the cancer. In some instances when skin must also be resected with the tumor, reconstructive surgery (e.g., muscle flaps and/or split-thickness skin graft options) is necessary to cover the wound defects. However, the ideal timing of this reconstruction has yet to be identified.

At the 2019 Annual Meeting of the American Association of Orthopaedic Surgeons in Las Vegas, we presented outcomes data from 491 patients who underwent excision of an extremity or trunk STS at our facility over a 10-year period. Eighty-one of those patients had associated soft-tissue reconstruction: 26 had primary reconstruction on the same day as the tumor resection surgery, and 55 had staged or delayed reconstruction with wound vacuum temporization.

Perhaps one reason that ideal procedure timing has yet to be elucidated is that the indications for primary vs. staged reconstruction are not defined. Many times, in surgery for STS, we have to remove skin with the tumor or evacuate a large area of muscle. The remaining skin may not be able to stretch enough to adequately close the wound. In these patients, plastic surgery reconstructive options to cover the defect with a split-thickness skin graft or flap are essential. For primary reconstruction, the plastic surgeon would operate immediately

following the excision, under the same episode of general anesthesia. In staged reconstruction, a wound vacuum is placed to temporarily cover the defect, and the plastic surgeon will bring the patient back at a later date for reconstruction after negative margins are confirmed. The question we sought to answer in this review was this: “Is there a difference in surgical or oncologic outcomes between primary and staged reconstruction following STS excision?”

### No significant difference in surgical outcomes

We found no significant difference in the surgical outcomes of patients who received primary or staged reconstruction. The mean time to reconstruction was 17 ± 15 days in the staged group.

Infection was the most common complication, with 10 superficial and 13 deep infections in the 81 surgeries. Forty-six percent of patients in the primary group and 53% of patients in the staged group had healed within three months. These differences were not statistically significant.

### No significant difference in most oncologic outcomes

When analyzing oncologic outcomes, we found no significant difference between primary and staged reconstruction.

*continued next page >*



**Nathan Mesko, MD**  
meskon@ccf.org  
216.444.4603



**Lukas Nystrom, MD**  
nystrol@ccf.org  
216.445.7164

	Primary reconstruction N = 26 (%)	Staged reconstruction N = 55 (%)	P value
Wound complications	15 (58)	25 (45)	0.347
INTERVENTION FOLLOWING COMPLICATION			
Surgery	9 (35)	16 (29)	
Wound care	4 (15)	6 (11)	
Antibiotics alone	2 (8)	3 (6)	

Table 1. Wound complications

TWO PATIENTS  
IN THE PRIMARY  
GROUP HAD  
POSITIVE MARGINS,  
AND NEITHER  
UNDERWENT  
AN ADDITIONAL  
EXCISION  
PROCEDURE.

	Primary reconstruction N = 26 (%)	Staged reconstruction N = 55 (%)	P value
Local recurrence	2 (8)	4 (7)	1.000
Metastasis after reconstruction	5 (19)	11 (20)	0.755
Wound care	7 (27)	15 (27)	1.000

Table 2. Oncologic outcomes

Significantly, 58% of patients in the primary reconstruction group required admission to the surgical intensive care unit (SICU) compared with only 22% in the staged group. Length of SICU stay, however, did not differ between the groups.

The number of surgeries was higher, at  $3.9 \pm 2.1$  in the staged reconstruction group compared with  $2.5 \pm 2.4$  in the primary group. When we looked at the total number of surgeries after reconstruction, however, we found no difference between the cohorts. There was also no difference in total anesthesia time.

#### Easier reintervention for positive margins

Staging the reconstruction appears to have been beneficial in cases where there were positive margins. Two patients in the primary group had positive margins, and neither underwent an additional excision procedure. Four patients in the staged reconstruction cohort had positive margins, and all four underwent further excision before reconstruction.

It can take up to a week after the initial excision to obtain an accurate margin evaluation. By staging reconstruction, we can confirm that the surgical margins are

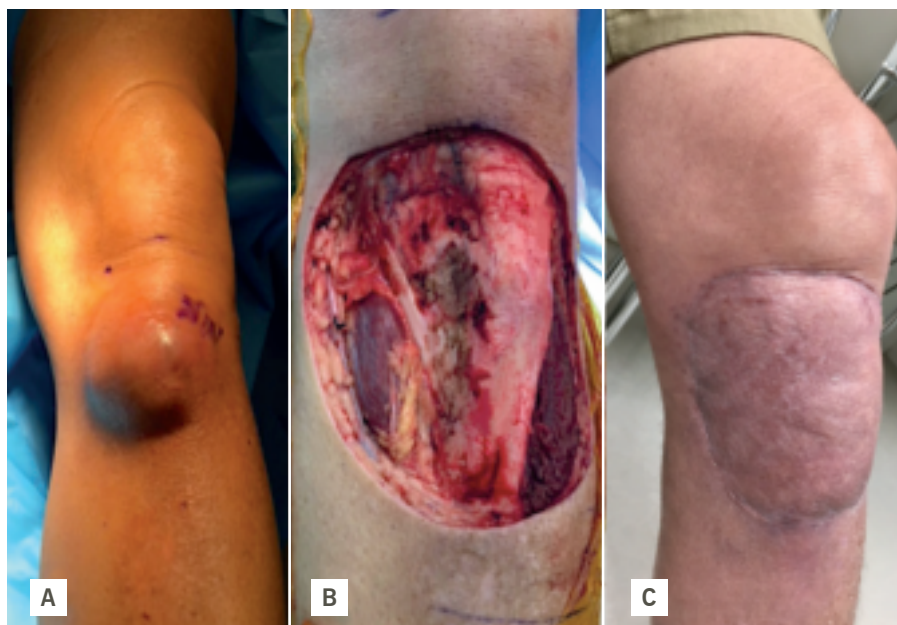negative. Routinely, with direct partnership and communication with our sarcoma pathology team, margin turnaround can be in as little as 24-48 hours, creating fewer delays between excision and definitive coverage of the wound. In staged cases, a delayed reconstruction affords easy reintervention following positive margins, with little additional morbidity.

In addition to the improved ease of reintervention with staged reconstruction, our study shows that immediate and long-term outcomes were no different between the primary and staged cohorts.

#### Staged reconstruction case example

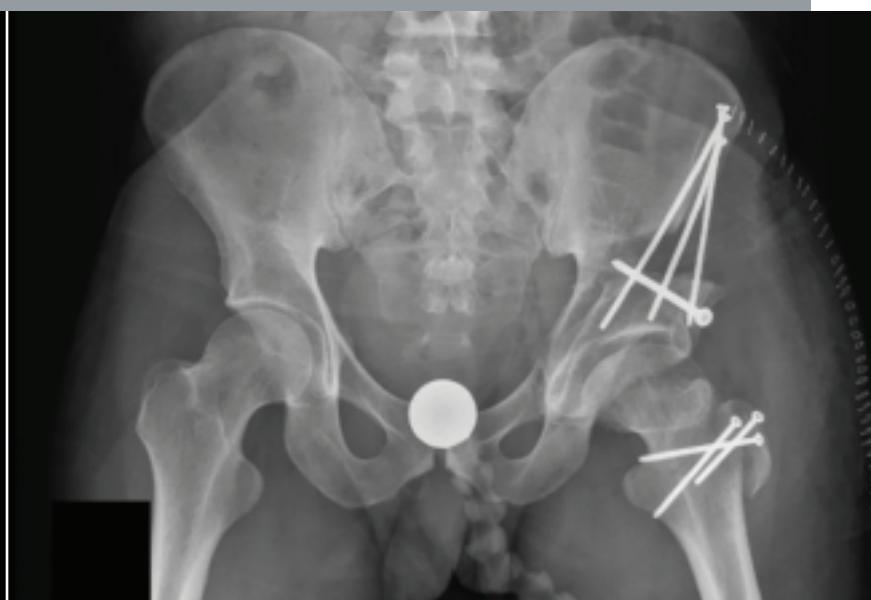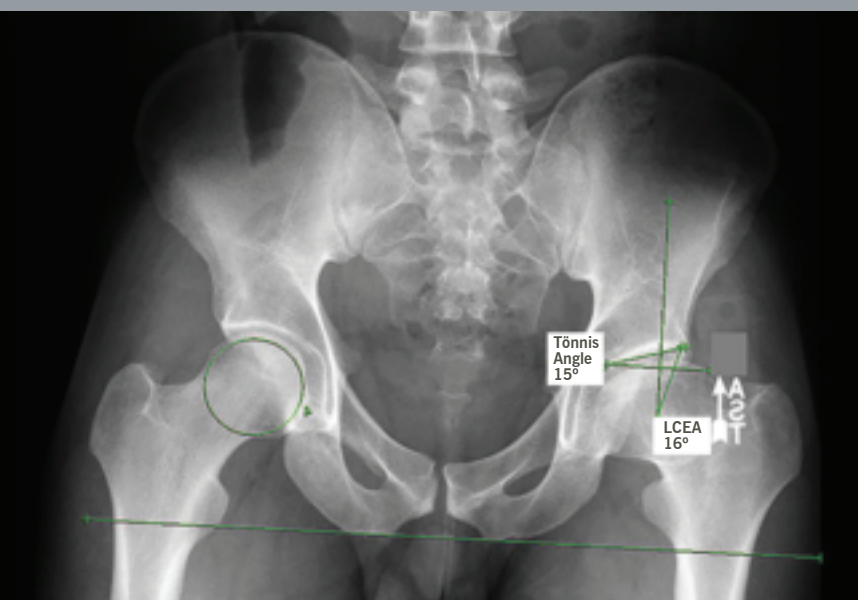
We performed a wide excision with wound vacuum temporization in a 63-year-old male with a high-grade STS of the proximal tibia. After confirming negative margins, we completed the staged reconstruction on postoperative day three. ■

**Nathan Mesko, MD**, is Section Head of Orthopaedic Oncology and Trauma, and Co-Director of the Sarcoma Center. **Lukas Nystrom, MD**, is a Staff physician who specializes in the surgical treatment of musculoskeletal tumors.



(A) Preoperatively, (B) During primary excision, and (C) Three months post soft tissue with a rotational gastrocnemius flap and split-thickness skin graft.

# COMPLEX, TWO-PART PROCEDURE PRESERVES HIP IN YOUNG ADULT WITH PERTHES DISEASE



A 28-year-old woman was referred to Cleveland Clinic's Center for Hip Preservation in the fall of 2018 with complaints of hip pain lasting several years. The patient described a continuous, aching pain localized to the left hip, left groin and left buttock. Activities of daily living exacerbated her pain, and she noted difficulty putting on shoes and socks. She also reported popping, catching and giving way.

On exam, the patient walked with a limp, favoring the left gait. The lateral aspect of the left hip was tender on palpation. The patient's right leg was approximately 0.25 inches longer than the left. In provocative tests, we found left-sided anterior impingement and limited range of motion due to pain.

Consistent with the patient's clinical history and examination, imaging revealed a Perthes deformity of the left hip with preserved joint space. The MRI revealed an acetabular labrum tear. Our patient's chronic instability was related to underlying bony acetabular dysplasia.

## **Surgical hip dislocation with greater trochanter advancement and relative head-neck lengthening**

The patient was placed in the lateral decubitus position for the left hip dislocation. We split the fascia, achieving safe access to the posterior aspect of the greater trochanter, and performed a trochanteric flip osteotomy

with a saline-cooled thin-kerf saw and then used broad osteotomes in completing our distal subvastus approach to the femur.

We exposed the hip capsule, then performed a Z-shaped capsulotomy and tagged the anterior and posterior flaps. Distally, we extended the capsulotomy to the level of the femoral neck. We could then safely dislocate the hip and perform the needed intra-articular work.

Using preoperative 3D surgical planning and dynamic assessment, we confirmed bony prominences that required decompression on the femoral side. We reconstituted the gentle waist of the femoral head and neck junction using a combination of osteotomes and a burr.

Finally, we closed the trochanteric flip osteotomy and fixed it with screws. We advanced the fragment several centimeters to improve the relative head-neck lengthening and abductor arm. We closed the trochanteric bursa over the screws and closed the subvastus approach to the femur.

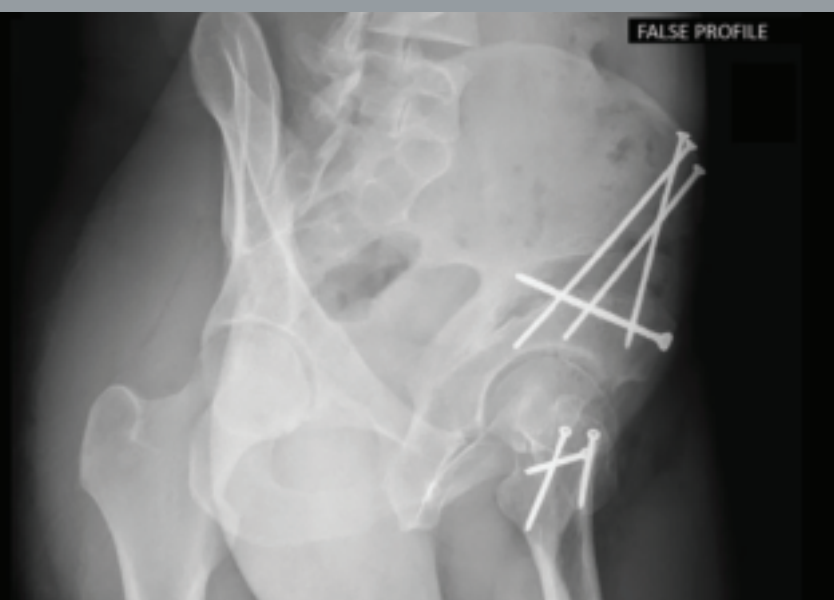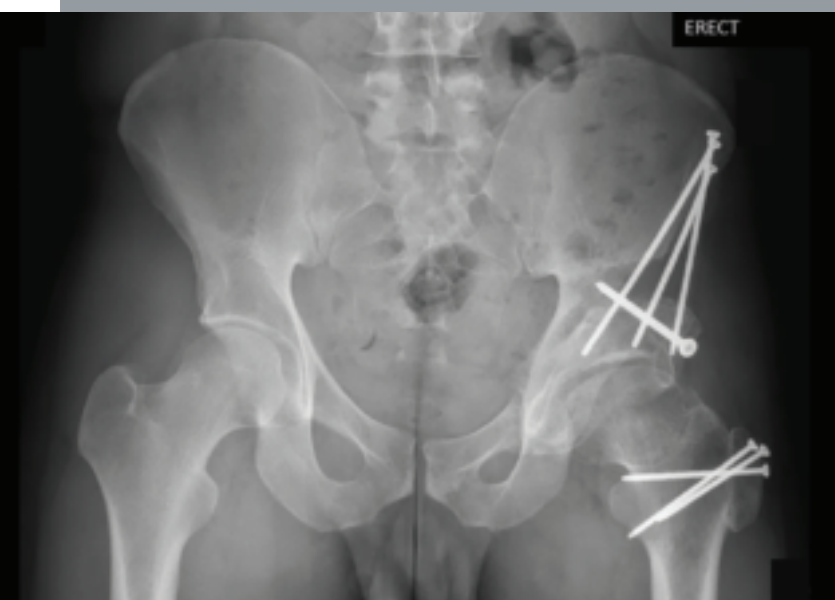## **Left periacetabular osteotomy**

Next, we placed the patient in the supine position. We used a standard Smith-Petersen approach starting slightly lateral to the iliac crest and approximately 5 cm proximal to the anterior inferior iliac spine



**Atul F. Kamath, MD**  
kamatha@ccf.org  
216.445.7408

*continued next page >*



AT THREE MONTHS  
POSTOPERATIVELY  
OUR PATIENT WAS  
ABLE TO MOVE HER  
HIP SMOOTHLY,  
WITH FLEXION TO  
100 DEGREES.

(AIIS). The incision was carried to the spine and then continued distally over the tensor-sartorius interval. We detached the sartorius from the spine and tagged it, and detached the insertion of the iliacus from the medial pelvic wall. Then, using periosteal elevators, we reached the sciatic notch laterally and the pelvic brim medially. We identified the rectus and detached its insertion on the AIIS. We then exposed the hip joint capsule and the pubis by elevating the iliopsoas.

We then developed the interval between the psoas and hip joint capsule medially and, using large scissors, encountered the ischium. We cleaned the soft tissue using a periosteal elevator and exposed the medial aspect of the ischium. Following subperiosteal dissection, we placed Kinder Eva retractors around the superior and inferior aspect of the pubis bone to protect the obturator nerve.

After completing the necessary periacetabular osteotomies, we inspected the posterior column and found it intact. The acetabular fragment was freely mobile. Once satisfactory global acetabular coverage was confirmed through intraoperative radiograph, we fixed the osteotomy with cortical screws and obtained excellent fixation.

We removed small fragments of bone from the anterior aspect of the inferior fragment and packed the osteotomy interstices with a demineralized bone matrix-cancellous bone allograft mixture.

Final intraoperative radiographs of the pelvis demonstrated satisfactory appearance of the reduction, fragment positioning and fixation construct. We rotated the hip through a range of motion, and there was no secondary impingement. Final neuromonitoring signals were stable.

We reattached the sartorius and rectus femoris tendons using nonabsorbable suture. We firmly reattached the iliac crest muscles and fascia, approximated the distal fascia, and then closed the wound.

#### **Patient no longer limping at three months**

At three months postoperatively our patient was able to move her hip smoothly, with flexion to 100 degrees. The incision was well-healed. On X-ray, the osteotomy and hardware appeared stable, and the patient had a stable gait with no assistive device. ■

*Atul Kamath, MD, is Director of the Center for Hip Preservation.*



# COMPREHENSIVE 3D IMAGING ANALYSIS MAY PREDICT RISK OF POST-TRAUMATIC OSTEOARTHRITIS FOLLOWING ACL REPAIR

Early bone-shape changes may predict the development and extent of post-traumatic osteoarthritis (PTOA), according to a new study published in *Osteoarthritis and Cartilage*.<sup>1</sup> Bone-shape changes following ACL repair (ACLR), as measured by comprehensive 3D imaging, may allow for interventions to reduce the severity of any future disease.

## The quest for a biomarker capable of predicting PTOA

Osteoarthritis is a complicated disease. Radiographs are not sensitive enough to detect subtle changes to joint structure that might be harbingers of arthritis. Our long-term goal with this research is to find a way for imaging to be used as a biomarker for people at high risk for developing osteoarthritis.

In this recent study, we used computational analysis of 3D MRI, statistical shape modeling and patient-reported symptoms to assess risk factors for the development of PTOA following ACLR. We sought to identify possible correlations between bone-shape changes and cartilage health over time.

We found that bone-shape changes — such as femur sphericity, notch width, tibial area and tibial slope — in the three years immediately following ACLR may be biomarkers for future PTOA. The statistical methods used in identifying bone-shape changes via 3D MRI quantify such bone-shape changes comprehensively without prior assumptions. They allow researchers to simply look at what the data show so they can generate hypotheses without bias.

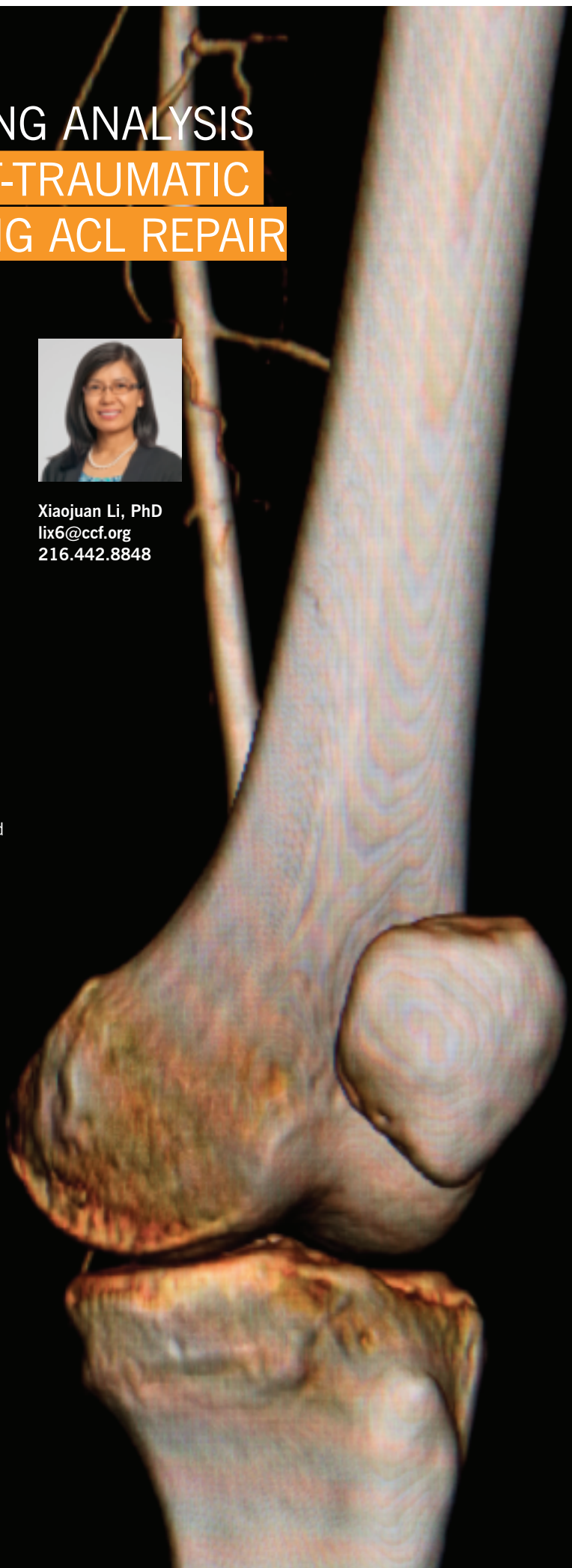For example, there are differences in the intercondylar notch width and tibial slope between people with ACL tears and healthy controls. With this method, we can scientifically confirm the variance using these images and analyses, and then measure how the differences progress over time.

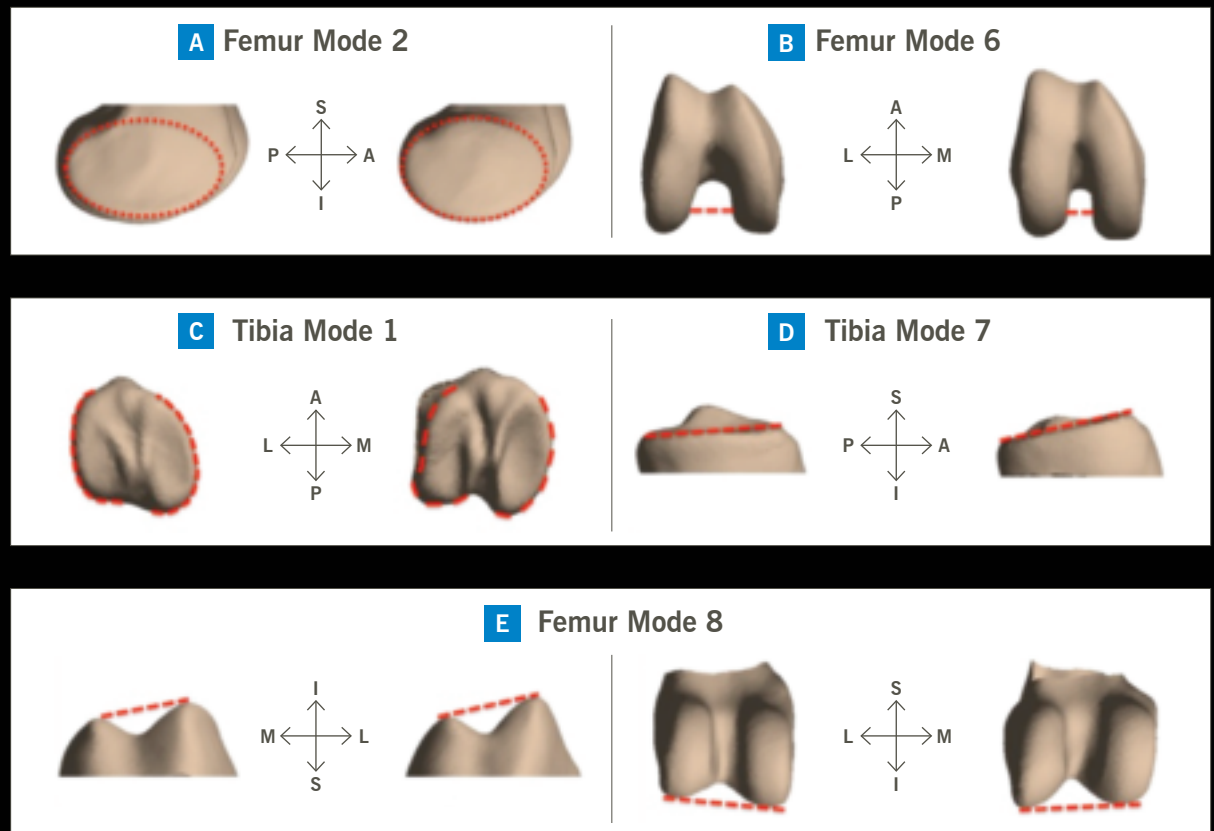
*continued next page* >



Xiaojuan Li, PhD  
lix6@ccf.org  
216.442.8848

3D MRI ENABLES THE QUANTIFICATION OF  
BONE-SHAPE CHANGES COMPREHENSIVELY,  
WITHOUT PRIOR ASSUMPTIONS. IT ALLOWS  
RESEARCHERS TO SIMPLY LOOK AT WHAT  
THE DATA SHOW SO THEY CAN GENERATE  
HYPOTHESES WITHOUT BIAS.





The physical interpretation of bone-shape modes. Left: representative shapes from control knees; right: representative shapes from ACL-injured knees. (A) Femur Mode 2: medial femoral condyle shape; (B) Femur Mode 6: notch width; (C) Tibia Mode 1: tibia plateau area; (D) Tibia Mode 7: medial tibia slope; (E) Femur Mode 8: trochlea inclination and medial femoral condyle height. A: anterior; P: posterior; S: superior; I: inferior; M: medial; L: lateral. Note: These shape features are the major ones associated with these modes. Each mode represents a whole set of 3D bone shape features.

### Identifying patients at risk while interventions may still be effective

Six months might not seem like enough time to see significant changes in bone shape; however, our study confirmed statistically significant changes in that short period. For example, the tibial plateau area, which at baseline was similar between both cohorts, became larger after injury. In patients with ACL tears, changes to the tibial area within the first six months following ACLR were mostly related to cartilage changes.

The ability to accurately predict which patients are at high risk for PTOA may provide the opportunity for preventive interventions. This modeling can identify patients who may benefit from early pharmaceutical intervention, possibly slowing the disease course or reducing symptom severity.

Next steps in this research involve building scale. We are working with the Arthritis Foundation<sup>SM</sup> to establish a nationwide infrastructure of charter sites that can recruit patients for pharmaceutical trials as they become available and from whom we can obtain imaging and biomarkers to give us data from a larger cohort. ■

### Reference

<sup>1</sup>Zhong Q, Pedio V, Tanaka M, et al. 3D bone-shape changes and their correlations with cartilage T1ρ and T2 relaxation times and patient-reported outcomes over 3-years after ACL reconstruction. *Osteoarthritis Cartilage*. 2019 Feb;27(6):915-921.

**Xiaojuan Li, PhD**, is Director of the Program for Advanced Musculoskeletal Imaging (PAMI) and holds the Bonutti Family Endowed Chair for Musculoskeletal Research.

# BEFORE AN INCISION IS EVER MADE: ARTIFICIAL INTELLIGENCE ACCURATELY PREDICTS THE ORTHOPAEDIC EPISODE OF CARE

In two recent studies, Cleveland Clinic's Orthopaedic & Rheumatologic Institute developed and validated a machine-driven automated algorithm for predicting, prior to total hip or knee arthroplasty, a given patient's length of stay (LOS) and inpatient cost of care.<sup>1,2</sup> The algorithm provides a patient-specific payment model, with tiered reimbursement according to the anticipated complexity of each case.

## The value of predicting the cost of care

We know that patients with major comorbidities are more likely to develop complications and require a longer LOS. The recent push from payers for bundled payments does not take into account the significant variation in our patients' ages and comorbidities. For example, a knee replacement in an otherwise healthy 55-year-old male should cost significantly less than the same procedure in a 70-year-old male with hypertension and poorly controlled Type 2 diabetes. When it comes to surgery, a one-size-fits-all approach to payment might increase the costs for providers, payers and patients alike.

The most significant findings of these recent studies is that we are much closer than we realize to predicting hospital courses and costs — before an incision is even made. With our commitment to collecting big data and the availability of greater computing power, we can now project the episode of care down to the level of the individual patient. Not all patients are created the same, and thus not all patients require the same resources or efforts. In these studies, we proposed a patient-specific payment model (PSPM) that more equitably distributes resources based on a given patient profile for arthroplasty procedures of the hip and knee.

## Big data/machine learning in medical practice lags that in online consumer space

Because our focus in medicine is on caring for people rather than providing entertainment or optimized shopping experiences for consumers, technological changes lag behind those of, say, Amazon or Netflix, which have more opportunity to experiment and rapidly innovate. Although change occurs at a more glacial—albeit safer—pace, we believe remaining thoughtful and

innovative in our application of artificial intelligence is critical if we are to better serve the people who entrust us with their lives. Moreover, we believe artificial intelligence (AI) and subsequent insights, like those derived from the PSPM, are here to stay.

## Fewer clicks and safer automation with EMRs

We believe these studies signal a new era in clinical workflow and research, which directly impacts patients, physicians and payers. Knowing how many resources a patient will need before surgery gives us the opportunity to plan and prepare to render patient-specific care. This is a previously uncharted advantage we at Cleveland Clinic are extremely excited to share with our professional community. For patients, this may mean fewer routine visits and less-disruptive days with smarter postoperative monitoring tools. For physicians, this may mean fewer clicks with safer automation when working with electronic medical records (EMRs). For payers, this may mean improved budgetary planning with fewer delays in care and “surprise” bills.

We are moving quickly in our study of AI and its impact on orthopaedics under the leadership of Cleveland Clinic's Viktor Krebs, MD, Vice Chair of Orthopaedic Surgery, and Brendan Patterson, MD, Chairman of Orthopaedic Surgery. We have recently established the world's first laboratory dedicated to studying the impact of AI on the practice of orthopaedic surgery. Our focus is on two areas: remote patient monitoring with recent telehealth initiatives, and value-based care tailored to each patient using evidence-based data, as demonstrated by the aforementioned PSPMs. ■

## References

<sup>1</sup>Ramkumar PN, Navarro SM, Haeberle HS, et al. Development and validation of a machine learning algorithm after primary total hip arthroplasty: applications to length of stay and payment models. *J Arthroplasty*. 2019 Apr;34(4):632-637.

<sup>2</sup>Navarro SM, Wang EY, Haeberle HS, et al. Machine learning and primary total knee arthroplasty: patient forecasting for a patient-specific payment model. *J Arthroplasty*. 2018 Dec;33(12):3617-3623.


**Prem Ramkumar, MD**, is a resident in Orthopaedic Surgery.



**Prem Ramkumar, MD**  
ramkump@ccf.org  
216.219.5953



# DEGREE OF OBESITY RELATES TO RISK OF POSTOPERATIVE COMPLICATIONS IN HIP AND KNEE ARTHROPLASTY



Carlos Higuera Rueda, MD  
higuerc@ccf.org  
954.659.5430



Nicolas Piuze, MD  
piuzin@ccf.org  
216.445.9190

The risk of developing major complications in the first 30 days following lower-extremity joint arthroplasty may be related to the severity of obesity, according to a series of studies we have published in the past several months. Our work suggests that, when it comes to evaluating surgical risks, it might be more accurate to consider body mass index (BMI) as a continuum rather than as a binary construct, with different weight categories correlated to different levels and types of postoperative complications. Understanding the interaction between BMI and complications is one way in which physicians are working to improve surgical outcomes.

We developed four retrospective cohort studies to assess obesity-related complications following total hip arthroplasty (THA) and total knee arthroplasty (TKA) using dynamic statistical analyses. We reviewed data from the American College of Surgeons National Surgical Quality Improvement Program database, including the length of hospital stay and 30-day complications from each procedure.

## BMI is a continuum with varying risks in joint replacement surgeries

In TKA, overweight patients had no higher overall complication risks than patients with BMIs in the normal range.<sup>1</sup> However, obese patients had an increased risk of developing a pulmonary embolism, and morbidly obese patients had increased risks of readmission, reoperation, superficial infection, periprosthetic joint infection, wound dehiscence, pulmonary embolism, urinary tract infection, reintubation and renal insufficiency.

HIGH-RISK PATIENTS DO NOT NECESSARILY HAVE TO REACH A HEALTHY WEIGHT TO IMPROVE SURGICAL OUTCOMES. THESE STUDIES PROVIDE SOME POTENTIAL GOALS FOR WEIGHT MANAGEMENT THAT COULD ENSURE A SAFER PROCEDURE.

In unicompartmental knee arthroplasty, BMI does not appear to impact a patient's risk of developing 30-day complications, with the exception of one: Morbidly obese patients did have an increased risk of developing superficial surgical site infection.<sup>2</sup>

In THA, increased BMI was correlated to increased readmissions, reoperation, superficial infection, prosthetic joint infection and sepsis.<sup>3</sup>

In terms of revision surgeries, there was a linear relationship between BMI and readmission and reoperation rates.<sup>4</sup> Obese patients had a lower risk of organ/space surgical site infection (SSI) compared with normal-weight patients. Morbidly obese patients, however, had an increased risk of developing superficial SSI. For TKA, the lowest rate of complications occurred in patients with a BMI of approximately 30 kg/m<sup>2</sup>. For THA, the lowest rate occurred for patients with a BMI of 28 kg/m<sup>2</sup>.

The studies revealed some key differences in how BMI affects complications based on joint replacement procedures. For example, the relationship between BMI and perioperative complications is stronger for revision TKA as opposed to revision THA.

## Set realistic BMI targets to minimize complications

The data showed that high-risk patients do not necessarily have to reach a healthy weight to improve surgical outcomes. These studies provide some potential goals for weight management that could ensure a safer procedure. For patients with very high BMIs, this offers a more realistic target to achieve in order to reduce their risk of complications.

While optimizing risk is very important, there is not always enough time to do so before surgery. Sometimes revision surgeries have to be performed immediately due to infection or pain caused by a previous surgery. The data revealed that revision surgeries involving total knee replacements carried a higher risk of complications as BMI went up, which was not always the case with total hip revision.



### Importance of patient education

Patient education on weight management is key to improving surgical outcomes following total joint replacement. Patients need to understand that obesity is a modifiable risk factor for elective surgery. Beyond surgical benefits, losing weight can improve a patient's life on many levels, enhancing quality of life and maximizing life expectancy.

It also helps if surgeons look at patients holistically and understand the complexities involved in treating obese patients. Then, we can recommend strategies to modify obesity, including bariatric surgery and weight loss programs.

BY TAILORING BIG DATA TO INDIVIDUALS,  
WE HOPE TO BETTER PREDICT THE  
OUTCOMES FOR THESE PATIENTS IF THEY  
UNDERGO SURGERY.

### Goals for future research and patient care

The BMI/joint replacement studies help explain the overall relationship between BMI and joint replacement outcomes. To continue this research, Cleveland Clinic received a grant that will help fund the development of personalized methods to apply similar data analysis to individual patients. By tailoring big data to individuals, we hope to better predict the outcomes for these patients if they undergo surgery. We would like to be able to assign a value to the patient's risk and then identify the appropriate BMI target needed to lower that risk.

Of course, our goal is to help patients reduce risk factors. But if high-risk patients do not succeed in losing weight, we need to be able to deliver proper surgical care. We want to create special programs and strategies for taking care of these patients; it all comes down to developing better approaches that lead to better care. ■

70 53 64  
SIT MACNA DOLOR  
AMETH CASCO AMETH

BMI

### References

- <sup>1</sup>George J, Piuze NS, NG M, Sodhi N, Khlopas AA, Mont MA. Association between body mass index and thirty-day complications after total knee arthroplasty. *J Arthroplasty*. 2018 Mar;33(3):865-871.
- <sup>2</sup>Sundaram K, Warren J, Anis H, et al. An increased body mass index was not associated with higher rates of 30-day postoperative complications after unicompartmental knee arthroplasty. *Knee*. 2019 Jun; 26(3):720-728.
- <sup>3</sup>Scully W, Piuze NS, Sodhi N, et al. The effect of body mass index on 30-day complications after total hip arthroplasty. *Hip Int*. 2019 Feb 5. Doi: 10.1177/1120700019826482. [Epub ahead of print]
- <sup>4</sup>Roth Z, Khlopas A, George J, et al. The effect of body mass index on 30-day complications after revision total hip and knee arthroplasty. *J Arthroplasty*. 2019 Feb 13. doi: 10.1016/j.arth.2019.02.005. [Epub ahead of print]

**Carlos Higuera Rueda, MD**, is Center Director of Orthopaedics and Rheumatology and Chairman, Levitetz Department of Orthopaedic Surgery at Cleveland Clinic Florida. **Nicolas Piuze, MD**, is a Staff physician who sees patients at Cleveland Clinic main campus and Cleveland Clinic Willoughby Hills Family Health Center.

# ORTHOBIOLOGICS UPDATE: THE SEARCH FOR REPRODUCIBLE EVIDENCE CONTINUES



**Jason Genin, DO**  
geninj@ccf.org  
440.260.3731



**Dominic King, DO**  
kingd2@ccf.org  
440.260.3731

The past two years have seen an abundance of anecdotal and clinical experience and 10 meta-analyses on orthobiologics, but it has been challenging to standardize protocols in order to create reproducible data.

Perhaps the largest study to date was published in February 2019, in the *American Journal of Sports Medicine*.<sup>1</sup> The trial followed 167 patients with knee osteoarthritis who received either platelet-rich plasma (PRP) or hyaluronic acid (HA) for 24 months. This double-blind, randomized clinical trial found both treatments improved knee function and symptoms over time. PRP was not superior to HA in terms of symptomatic or functional improvement at any point in the follow-up period. The only significant difference between the two injection types was in the reintervention rate (i.e., the number of patients who underwent a new injective or surgical treatment of the joint). Patients who received PRP injections were able to go for longer periods before reintervention. Considering the potential for infection with each injection or surgery, this finding is clinically relevant.

A smaller (N = 53) randomized, controlled, single-center trial was published in *Arthroscopy* in January 2019, which compared the effects of injections of leukocyte-poor platelet-rich plasma (LPPRP) to HA or saline solution in patients with knee osteoarthritis.<sup>2</sup> One year out, only patients receiving LPPRP had sustained improvements based on the Western Ontario and McMaster Universities Osteoarthritis Index (WOMAC; increased by 2%) and International Knee Documentation Committee (IKDC; increased by 40%).

These two studies are a step in the right direction, but they do not provide categorical support for the use of PRP injections. Outside of those two studies, we have not seen much in the way of new, high-quality research for knee osteoarthritis. Some good efforts are underway to generate more data to support these practices. The main development in the past year or so, in our opinion, is that researchers are collaborating to move the field forward.

## No evidence that orthobiologics can regenerate tissue

In discussions with patients, we are careful to emphasize that PRP is not going to regenerate their cartilage, though PRP does appear to improve function and reduce pain. Right now, nothing on the market can regenerate or repair any type of cartilage or tendon fiber. We advise our patients to be wary of any facility or brand that uses those descriptive words to sell their products.

## Multiple treatment options

When patients come in looking for an injection, we look for simple, straightforward things that have worked in the past, such as physical therapy and rehabilitation, neuromuscular stimulator device use, any benefits from previous surgeries, etc. Our goal is always to optimize a patient's joint health, whether we use conservative techniques or injections, to potentially delay or optimize a patient for surgery.

## Importance of treatment sequencing

Getting the sequencing of different treatments right for each patient impacts outcomes. Patient education is an important part of the referral process — we want patients to understand why they were referred to orthopaedics. Some patients are pleased if we can delay surgery by even one year with interventions. However, we often see patients who have experienced pain for five to six years, and injections are their last-ditch effort to avoid surgery. This is likely not the most beneficial time to begin the discussion of orthobiologic therapies, as a total joint replacement may likely be their only option.

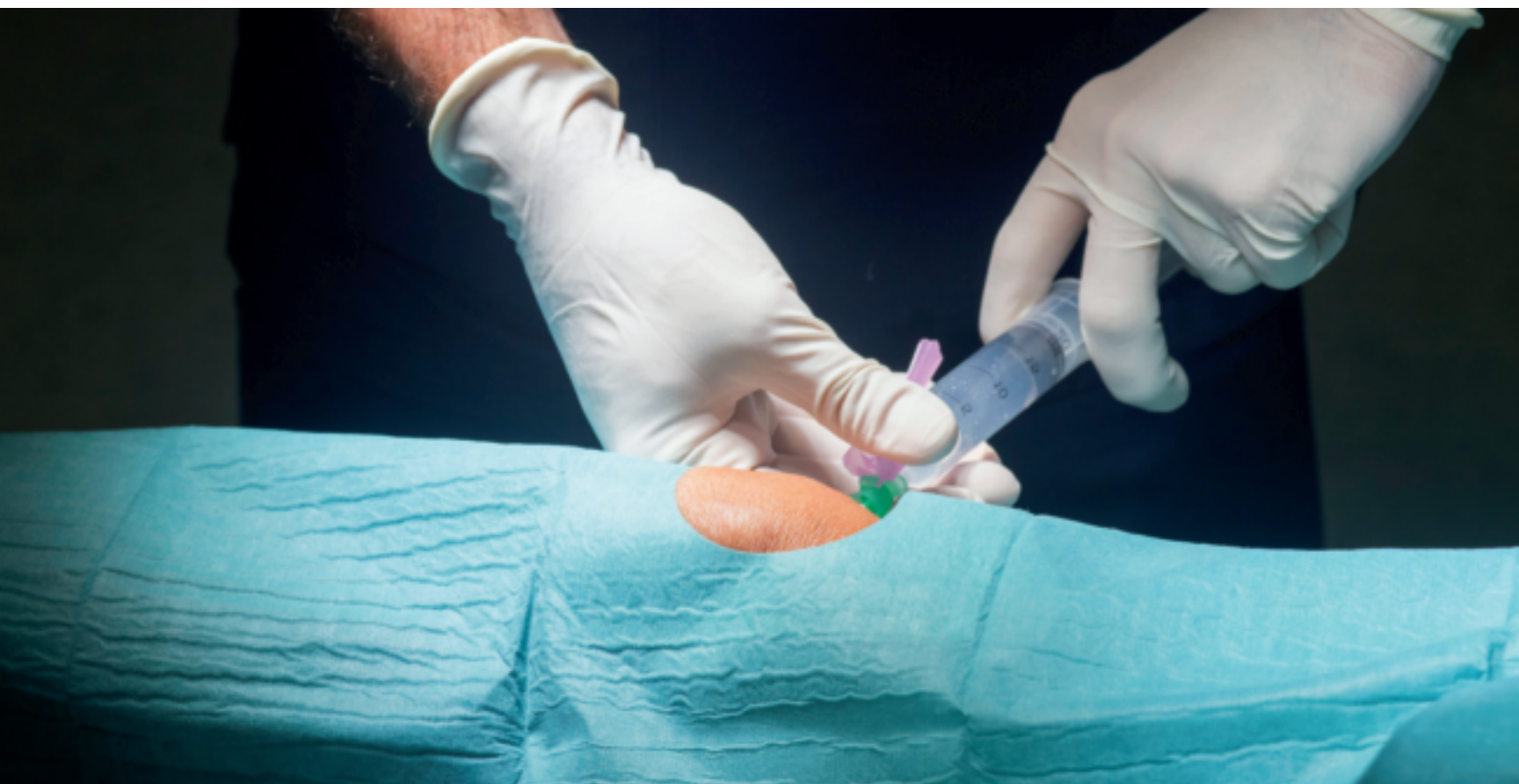Generally speaking, we look beyond the problematic joint to focus on the whole patient: Are there deformities that can be corrected? Can the patient modify activities, particularly intense exercise like long-distance running, until the inflammation settles down? Is the patient moving enough to encourage circulation in the joint? Is the patient overweight? We continue to tell our patients that weight loss, physical therapy and bracing go a long way toward reducing pain and optimizing their joint health prior to surgical intervention. ■

IN DISCUSSIONS WITH PATIENTS, WE ARE CAREFUL TO EMPHASIZE THAT PRP IS NOT GOING TO REGENERATE THEIR CARTILAGE, THOUGH PRP DOES APPEAR TO IMPROVE FUNCTION AND REDUCE PAIN. RIGHT NOW, NOTHING ON THE MARKET CAN REGENERATE OR REPAIR ANY TYPE OF CARTILAGE OR TENDON FIBER.

#### References

- <sup>1</sup>Di Martino A, Di Matteo B, Papio T, et al. Platelet-rich plasma versus hyaluronic acid injections for the treatment of knee osteoarthritis: results at 5 years of a double-blind, randomized controlled trial. *Am J Sports Med.* 2019 Feb;47(2):347-354.
- <sup>2</sup>Lin KY, Yang CC, Hsu CJ, Yeh ML, Renn JH. Intra-articular injection of platelet-rich plasma is superior to hyaluronic acid or saline solution in the treatment of mild to moderate knee osteoarthritis: a randomized, double-blind, triple-parallel, placebo-controlled clinical trial. *J Arthroscopy.* 2019 Jan;35(1):106-117.

*Jason Genin, DO, and Dominic King, DO, are Staff physicians in Cleveland Clinic's Sports Health Center.*






# ACCURACY OF 3D PLANNING, IMPLANT TEMPLATING AND PATIENT-SPECIFIC INSTRUMENTATION IN ANATOMIC TOTAL SHOULDER ARTHROPLASTY



**Eric Ricchetti, MD**  
ricchee@ccf.org  
216.445.6915



**Joseph Iannotti, MD, PhD**  
iannotj@ccf.org  
954.659.6538

Glenoid component loosening is the most common long-term complication following anatomic total shoulder arthroplasty (TSA). Accurate placement of the glenoid component is expected to decrease component malposition and better correct pathologic deformity in order to decrease the risk of component failure over time. However, achieving this goal may be challenging due to difficulties in determining the degree of preoperative pathology that is present, determining the best implant and correcting the pathology at the time of surgery.

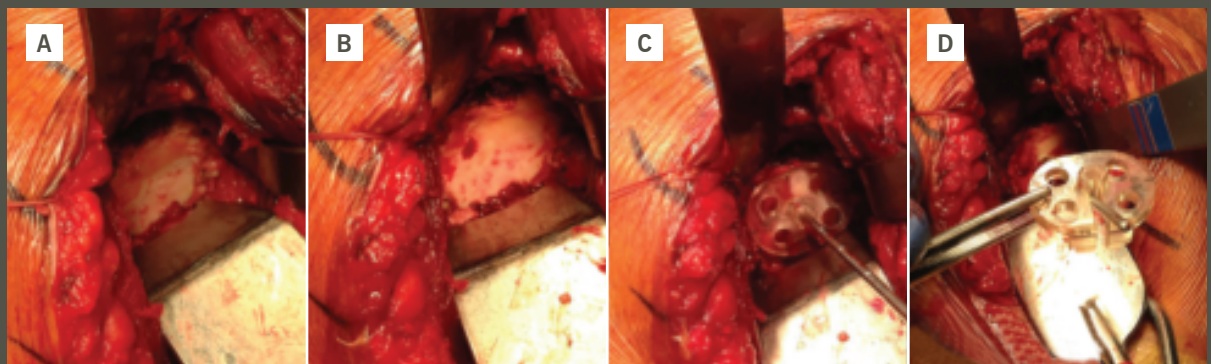
Prior studies have demonstrated inaccurate glenoid component placement when using standard surgical instruments and 2D imaging without implant templating, particularly as the degree of glenoid deformity or bone loss worsens. In contrast, improved accuracy of glenoid component placement has been demonstrated using 3D computed tomography (CT) preoperative planning and patient-specific instrumentation (PSI). However, studies comparing the use of different intraoperative tools are still lacking.

We sought to compare the accuracy of glenoid implant placement in primary anatomic TSA when using 3D CT preoperative planning with different types of standard and patient-specific instrumentation.

## Improved accuracy in all treatment groups

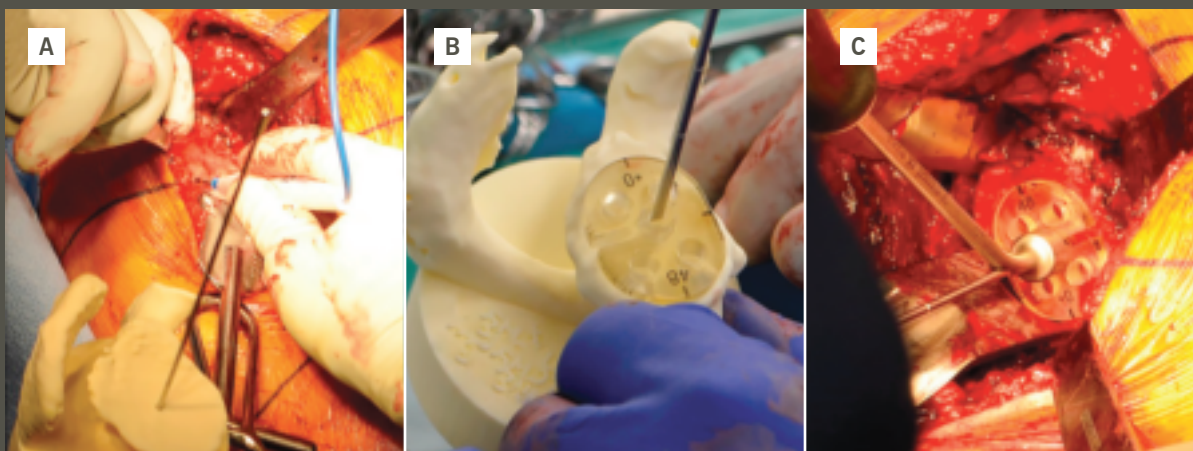
We enrolled 173 patients with end-stage glenohumeral arthritis undergoing primary anatomic TSA in three prospective clinical studies evaluating 3D CT preoperative planning with implant templating and PSI. All patients underwent preoperative 3D CT planning to determine optimal glenoid component and guide pin position based on surgeon preference. Patients were then placed into one of five instrument groups used for intraoperative guide pin placement: (1) standard instrumentation (SI); (2) SI combined with a 3D glenoid bone model (BM) containing the guide pin; (3) BM combined with a single-use PSI; (4) BM combined with a reusable PSI; and (5) use of reusable PSI with an adjustable, reusable base.

Postoperatively, all patients underwent a 3D CT with metal-artifact reduction within four months of surgery to compare actual versus planned glenoid component position. Deviation from plan was assessed by component orientation (version and inclination in degrees) and location (anteroposterior and superoinferior position in millimeters) and was compared across groups based on absolute differences and outlier analysis. Univariable and multivariable comparisons were performed, with three major treatment groups evaluated and compared in the final analysis: standard instrumentation



Intraoperative photographs of standard instrumentation (Group 1). **(A)** Shows a B2 glenoid with a paleoglenoid having some remaining soft tissue and the bone surface of the posterior neoglenoid. **(B)** Shows the soft tissue removed from the paleoglenoid and an anterior osteophyte. **(C-D)**: A pin guide with a 7 mm posterior step is placed with the flat surface of the anterior portion of the pin guide resting on the paleoglenoid and the posterior step of the guide placed on the neoglenoid. This orients the guide pin slot to be in line with the planned location and orientation of the guide pin as defined by the preoperative plan. After the guide pin is placed through the guide, its location is verified with the pictures from the preoperative plan.





Intraoperative photographs demonstrating use of a bone model for guide pin placement using standard instrumentation (Group 2). **(A):** A sterile bone model of the patient's glenoid with the guide pin in the location and orientation from the preoperative plan. The location of the pin is marked on the glenoid surface based on a visual inspection of the bone model. **(B):** A pin guide is placed onto the bone model over the guide pin so that the guide is perpendicular to the pin. In this case, a flat-backed pin guide (without augmentation) achieves that result. If there were posterior bone loss, then the correct pin guide would be augmented. **(C):** The pin guide is removed from the bone model and placed in the same location and orientation on the glenoid surface, with the pin placed through the slot provided in the guide.

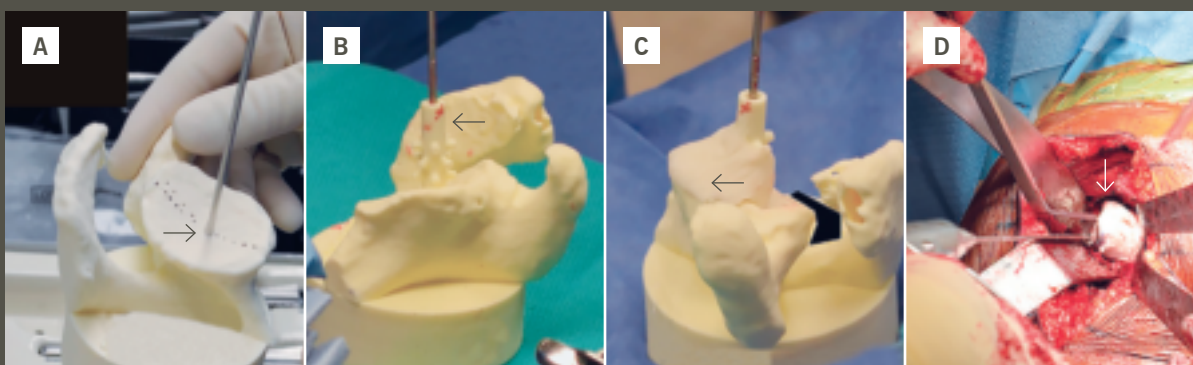
(Groups 1, 2) versus single-use PSI (Group 3) versus reusable PSI (Groups 4, 5).

In nearly all comparisons, there were no significant differences in deviation from plan (absolute differences, outlier frequency) for glenoid component orientation or location across the three major treatment groups, with all the treatment groups demonstrating improved accuracy when compared with historical controls that utilized 2D CT imaging without implant templating and standard surgical instruments. The reusable PSI group did show a significantly lower frequency of outliers for glenoid component version at the  $> 10$  degree

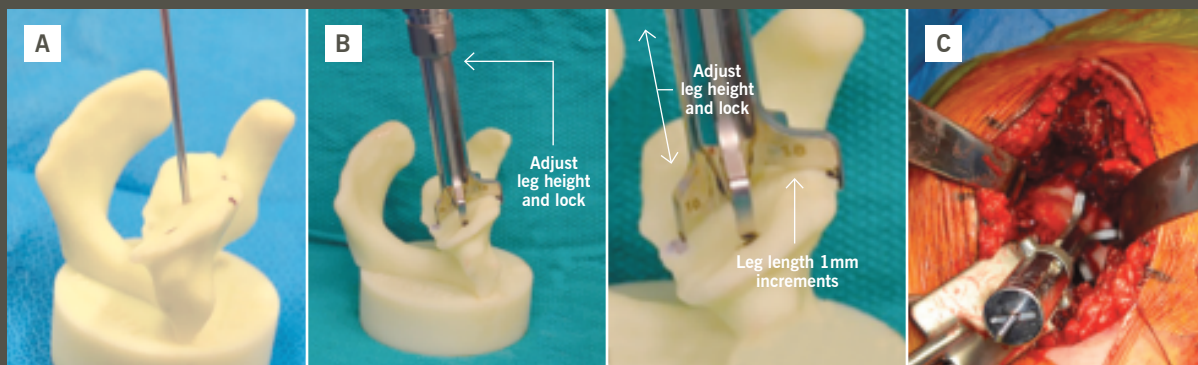
threshold compared with the other two treatment groups on univariable analysis.

This study did not demonstrate consistent differences in the accuracy of glenoid component placement in primary anatomic TSA with regard to different standard and patient-specific instrumentation technologies when used in combination with 3D CT preoperative planning for intraoperative guide pin placement. These results may suggest that the 3D CT preoperative planning used in all the treatment groups had the largest impact in improving accuracy of glenoid component placement in most cases, a finding noted in our prior study.

*continued next page >*



Intraoperative photographs demonstrating the use of a bone model and polymethyl methacrylate (PMMA) cement mold for guide pin placement (Group 3). **(A):** A sterile bone model containing the guide pin (arrow) is compared to patient's exposed glenoid surface. A thin layer of bone wax is placed onto the bone model in an area that is easily accessible on the glenoid surface and is best represented by the model. **(B):** A sleeve (arrow) is placed over the guide pin. **(C):** PMMA bone cement (arrow) in its late doughy stage is placed over the selected area of the bone model incorporating the sleeve. **(D):** Once the mold (arrow) is hardened, it is removed from the bone model and placed on the glenoid surface in the same location as the model, and a guide pin is placed through the sleeve of the mold.

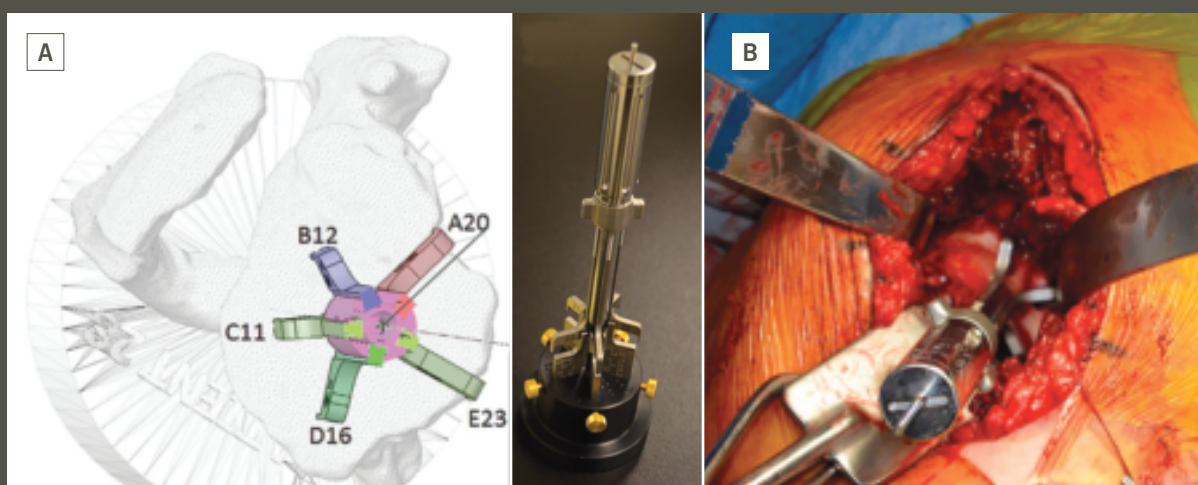


Intraoperative photographs demonstrating the setting of a reusable PSI tool using a bone model (Group 4). **(A):** A sterile bone model with guide pin is used. Marks are placed in specified locations on the bone model. **(B):** A specified leg is placed in each of five slots on a reusable cannulated pin guide. Each leg has a specified foot length. The cannulated handle is placed over the guide pin and each leg oriented over the specified mark on the bone model. The height of each leg is adjusted so that the foot contacts the bone model at each of the marked locations. This defines the height of the legs. The legs are locked into that location by turning a collet on the middle of the cannulated handle. **(C):** Once locked, the tool is removed from the bone model and placed onto the same location of the glenoid surface. The guide pin is placed through the cannulated handle into the bone. The location and orientation of the guide pin in the glenoid is verified by comparing it to the bone model.

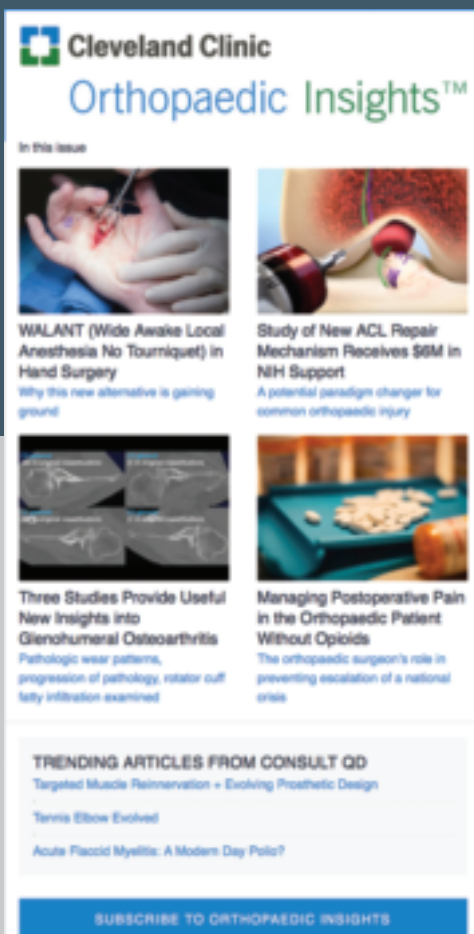Surgeons have multiple standard and patient-specific instrumentation options available at the time of surgery for improving accuracy of glenoid implant placement when used in combination with 3D CT preoperative planning. The surgeon should determine the best instrumentation for achieving the desired outcome based on cost, time to delivery and the surgeon's experience. ■

**Eric Ricchetti, MD**, is Director of the Shoulder Surgery Center and a shoulder surgeon in the Department of Orthopaedic Surgery.

**Joseph Iannotti, MD, PhD**, is Chief of Staff of Cleveland Clinic Florida and a shoulder surgeon in the Levitz Department of Orthopaedic Surgery.



Preoperative and intraoperative photographs of the reusable PSI tool shown with an adjustable, reusable base. **(A):** A virtual model of the reusable PSI tool is placed within the 3D CT preoperative planning software. The guide is placed over the guide pin in the software; the legs are selected for each slot and placed in the desired location on the bone within the software. The height of each leg is adjusted within the software to contact the virtual bone in the desired locations. The software then provides a height reading for each leg. **(B):** In the operating room, a sterile and adjustable base has five posts that are adjusted to specified heights and locked in place with brass thumb screws. The cannulated pin guide is then placed over the guide pin on the adjustable base. The legs of the pin guide contact each post and are locked into position by turning the collet in the center of the handle. The pin guide is removed from the base and placed onto the glenoid surface as shown on the virtual model, and a guide pin is placed through the handle into the bone. The location and orientation of the guide pin in the glenoid are verified with the pictures from the preoperative plan.



► For the latest research and insight from Cleveland Clinic's department of orthopaedic surgery, don't miss the quarterly *Orthopaedic Insights™* e-newsletter.

VISIT [CLEVELANDCLINIC.ORG/ORTHOINSIGHTS](https://clevelandclinic.org/orthoinsights)  
TO SUBSCRIBE TODAY.



Every life deserves world class care.

9500 Euclid Ave., Cleveland, OH 44195

The Orthopaedic & Rheumatologic Institute brings together physicians, researchers and engineers to pursue excellence and innovation in the care of patients with joint, bone, muscle, connective tissue and immune disorders. The Orthopaedic & Rheumatologic Institute is one of 26 clinical and special expertise institutes at Cleveland Clinic, a nonprofit academic medical center ranked as one of the nation's top hospitals by *U.S. News & World Report*, where more than 3,900 staff physicians and researchers in 180 specialties collaborate to give every patient the best outcome and experience. [clevelandclinic.org](https://clevelandclinic.org)

©2019 The Cleveland Clinic Foundation



The Cleveland Clinic Foundation  
9500 Euclid Ave. | AC311  
Cleveland, OH 44195



# ORTHOPAEDIC INSIGHTS

SUMMER 2019

## 24/7 Referrals

**855.REFER.123** (855.733.3712)  
[clevelandclinic.org/refer123](http://clevelandclinic.org/refer123)

### OUTCOMES DATA

View Outcomes books at  
[clevelandclinic.org/outcomes](http://clevelandclinic.org/outcomes)

### CME OPPORTUNITIES

Visit [ccfcme.org](http://ccfcme.org) for live and online offerings from  
Cleveland Clinic's Center for Continuing Education.

## Stay Connected with Cleveland Clinic's Orthopaedic & Rheumatologic Institute

### CONSULT QD – ORTHOPAEDICS

News, research and perspectives from Cleveland Clinic experts.  
[consultqd.clevelandclinic.org/topics/orthopaedics](http://consultqd.clevelandclinic.org/topics/orthopaedics)



[Facebook.com/CMECLandClinic](https://www.facebook.com/CMECLandClinic)



[@CleClinicMD](https://twitter.com/CleClinicMD)



[clevelandclinic.org/MDlinkedin](http://clevelandclinic.org/MDlinkedin)



[clevelandclinic.org/ortho](http://clevelandclinic.org/ortho)