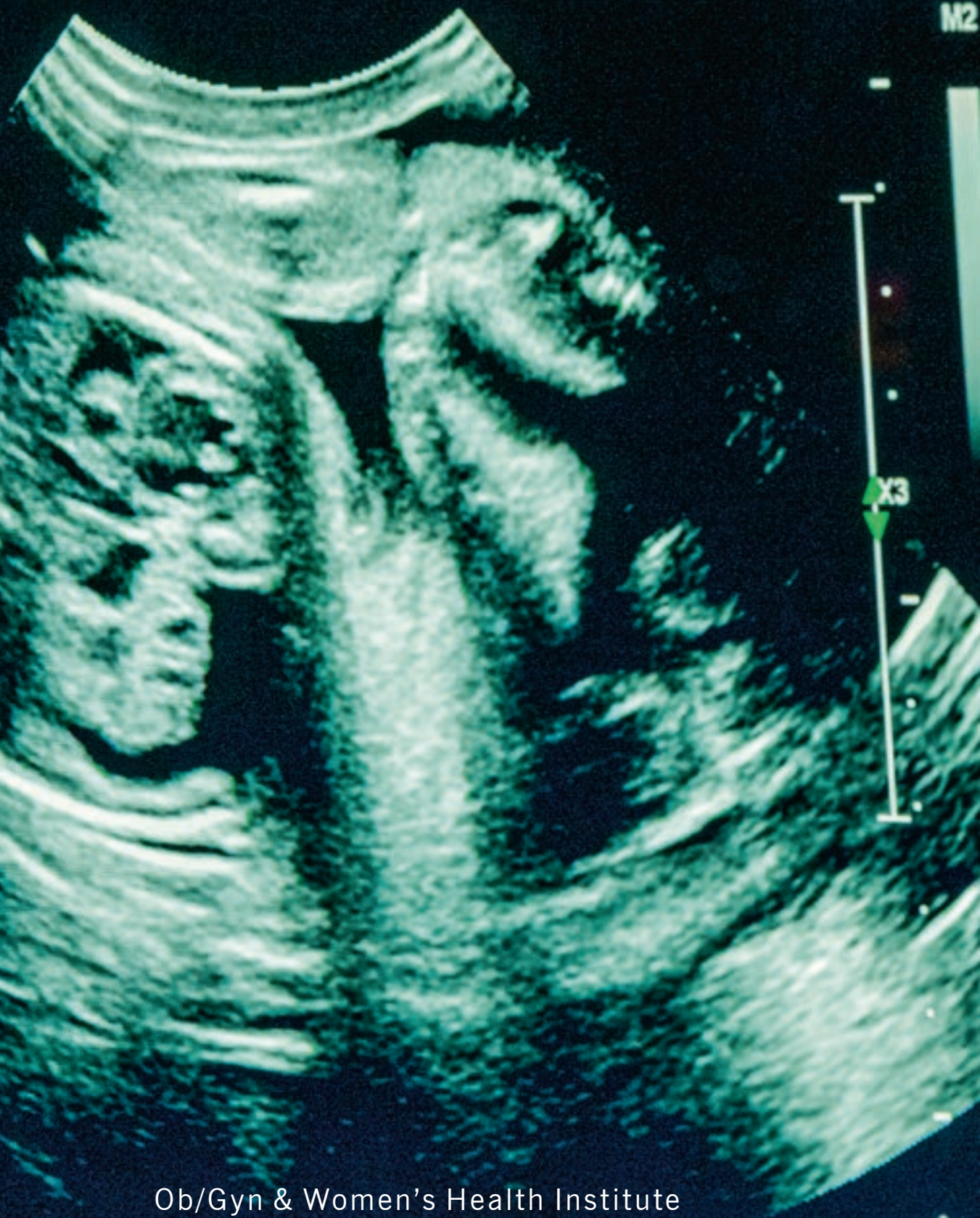

Ob/Gyn & Women's Health Institute

2021 Year in Review

MESSAGE FROM THE CHAIR

Dear Colleagues,

I am pleased to share with you the 2021 *Year in Review*, which highlights notable news and research from Cleveland Clinic Ob/Gyn & Women's Health Institute and underscores the many ways we support patient health and wellbeing.

As I write this, I am just weeks into my tenure as institute Chair after having been Chair of Obstetrics and Gynecology at Houston Methodist Hospital. As a onetime Cleveland Clinic Fellow, I bring longstanding admiration for the life-changing work this hospital does in the sphere of women's health.

Among highlights of this *Year in Review* is the cover story, which describes the successful efforts of a multi-disciplinary team of Cleveland Clinic specialists to remove an intrapericardial teratoma that posed a lethal risk to a 27-week-old fetus. The article illuminates the case complexities and the decisions the team faced along the way.

Within the realm of fertility treatment, there is an encouraging research story about the use of artificial intelligence to record the activity of blastocysts. The resulting data holds promise for optimizing selection of embryos for successful implantation.

And in an article about research ethics, Ruth M. Farrell, MD, MA, Vice Chair of Research for our institute, articulates the need to consider the impact on any study participant who might someday carry a genomically modified human embryo. Dr. Farrell and Marsha Michie, PhD, of Case Western Reserve University's Department of Bioethics, received a \$1.77 million National Institutes of Health grant to further examine the topic.

Some persistent challenges follow us into 2022. COVID-19 continues to threaten public health and to place enormous burdens on the healthcare system — especially hospital workers. The virus and the life-saving vaccines developed to fight it will continue to be topics of concern for those who are pregnant or trying to conceive. As physicians, we must continue to be advocates for our patients by sharing what the science shows us: that the virus poses a far higher risk to a pregnant woman than any risk of the vaccine.

Likewise, barriers to affordable, accessible healthcare remain all too common. At Cleveland Clinic, executive leadership has established healthcare equity and access as a priority. I look forward to being part of a team dedicated to finding solutions.

Alongside persistent challenges come opportunities to explore innovative treatments and technologies as well as novel approaches to patient care. We are all privileged to be part of these advances as we pursue work that we love in the field of women's health.

I wish you the best for 2022.

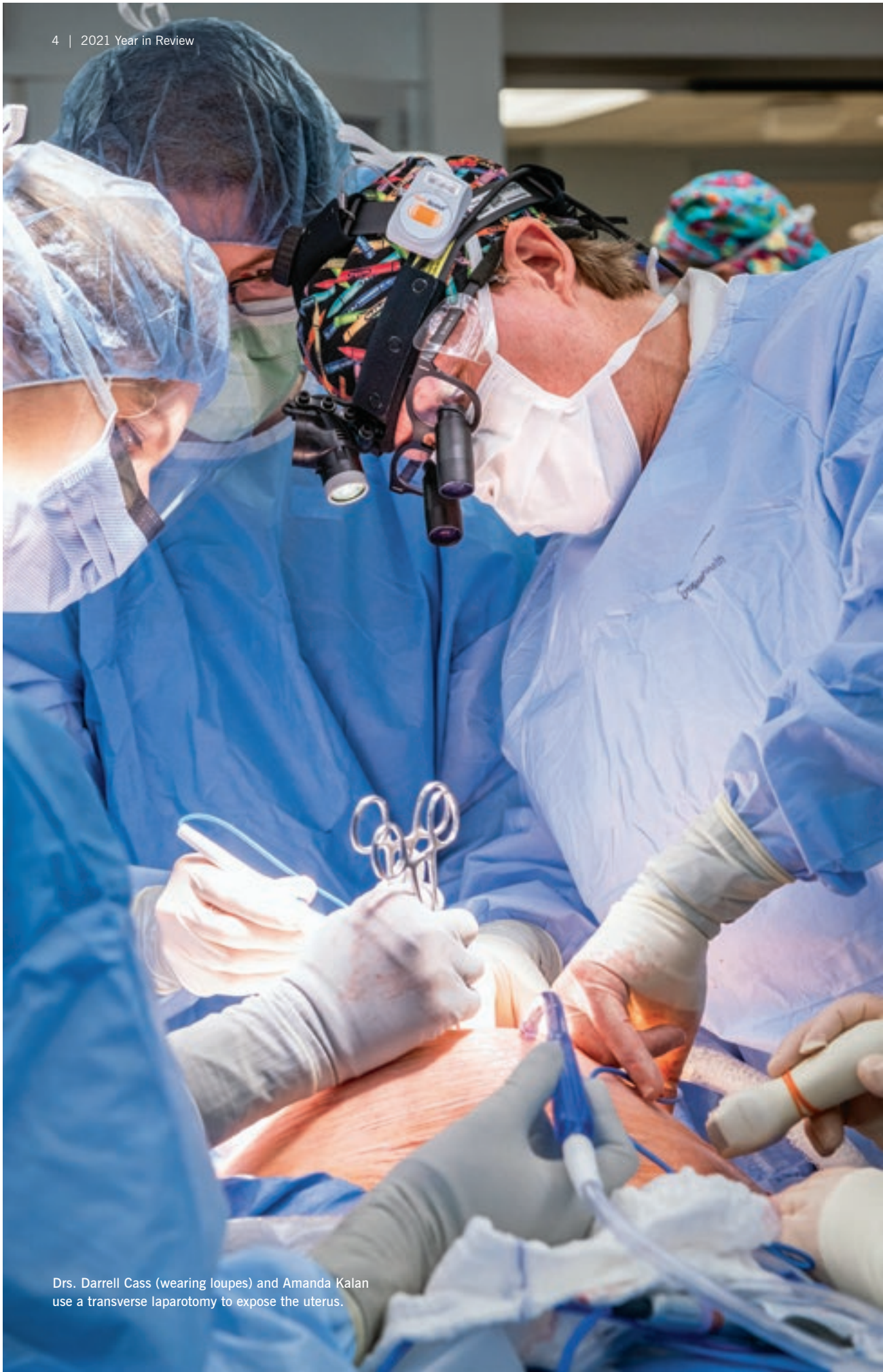Sincerely,

Tristi Muir, MD

Chair, Ob/Gyn & Women's Health Institute
216.445.0611, muirt@ccf.org

On the cover: Intraoperative echocardiogram imaging allows a team to track fetal heart function in real time during a challenging fetal surgery to remove an intrapericardial teratoma. Read more on page 5.





Drs. Darrell Cass (wearing loupes) and Amanda Kalan use a transverse laparotomy to expose the uterus.

Cleveland Clinic Fetal Surgeons Resect Rare Intrapericardial Teratoma

Continued pregnancy and delivery are only the second successful outcome worldwide

A multidisciplinary Cleveland Clinic team led by Darrell Cass, MD, has successfully performed a challenging fetal surgery to remove an intrapericardial teratoma that posed imminent lethal risk to a nearly 27-week-old fetus.

The operation in May to excise a 3-centimeter tumor affixed to the left side of the fetus's heart relieved severe cardiac compression and other physiologic problems and enabled the baby boy to be delivered near term 10 weeks later. After recovering from a lung infection, the infant was discharged.

Only one previous incidence of extended survival after fetal intrapericardial teratoma resection is documented in medical literature. In that 2013 case at Children's Hospital of Philadelphia (CHOP), the surgery took place earlier in gestation, when the complications caused by the tumor were not as advanced as those of the patient referred to Cleveland Clinic.

"This case is as hard as they come," says Dr. Cass, who founded the fetal surgery program in 2018 and is its director. "There are only a few comprehensive fetal surgery programs that have the personnel and infrastructure to tackle this. Close collaboration is essential, and every team member has to perform at the absolute top of their game. We have an amazing team."

Dr. Cass praised Hani Najm, MD, Chair of Pediatric and Congenital Heart Surgery, who removed the tumor, assisted by pediatric and congenital heart surgeon Alistair Phillips, MD; pediatric cardiologist Francine Erenberg, MD, who monitored the fetus's heart pre-, intra- and postoperatively and helped with resuscitation; obstetric and pediatric anesthesiologists McCallum Hoyt, MD, Tara Hata, MD, and Yael Dahan, MD, who administered maternal and fetal anesthesia;

and maternal-fetal medicine specialist Amanda Kalan, MD, who participated in the hysterotomy and managed the mother's obstetric care.

Assessing limited options

The mother's obstetrician promptly referred her to Cleveland Clinic's Fetal Care Center after a routine ultrasound in the fetus's 25th gestational week revealed a chest mass suspected of being a teratoma.

Intrapericardial teratomas are rare cardiac primary tumors that can occur either pre- or postnatally. Although typically benign, their rapid prenatal growth in confined space and close proximity to the fetal heart can cause cardiac tamponade and cardiopulmonary distress.

Tumors that arise late in gestation with small effusion can be monitored until delivery and excised in the neonatal period. Early-appearing and fast-growing intrapericardial teratomas with significant effusion require prenatal intervention. Several prenatal treatments — including pericardiocentesis, thoraco/pericardio-amniotic shunting, ex utero intrapartum treatment (EXIT) and open fetal surgery — have been attempted. Published accounts are limited, and there is no evidence-based consensus on management.

Fetal echocardiograms of the Cleveland Clinic patient revealed a fast-growing intrapericardial tumor affixed to the left atrium near the atrioventricular groove. The tumor was causing a massive pericardial effusion, progressive hydrops fetalis with bilateral pleural effusions and a small amount of ascites, dilation of the inferior vena cava and mild to moderate tricuspid regurgitation due to elevated pressure on the right

(continued)

(continued)

fetal heart. There was retrograde blood flow from the posterior descending artery to the transverse and ascending aorta.

The fetal care team estimated that, without intervention, cardiac compression from the tumor would prove fatal within 3 to 14 days.

“The question was how to manage it initially, or at all,” Dr. Erenberg says.

Although the parents favored treatment, the team had few viable options to consider.

Needle aspiration of the pericardium, in addition to posing a risk of uncontrolled hemorrhage if the heart was inadvertently pierced, likely would only provide a few days’ respite from fluid accumulation and cardiac compression. The same was true of shunting. Further, “we were worried that draining the effusion could change the axis of the heart and cause immediate heart failure,” Dr. Cass says.

In this case the tumor’s physical bulk, not just fluid exudate into the closed pericardium, was compromising cardiac function by obstructing the filling of the left ventricle, causing the left atrium to become increasingly dilated from the backup. “We didn’t think draining the pericardial effusion would make a difference with that problem,” Dr. Cass says. Furthermore, “we know that left ventricular filling in utero is important for left ventricular function and development, and there was no left ventricle filling. So we were concerned that hypoplasia of the left heart might be developing.”

The EXIT procedure — in which the fetus is partially extracted from the opened uterus for tumor resection while remaining on uteroplacental gas exchange, followed by separation and delivery — was not feasible in this case because of the gestational age and lung immaturity in the setting of hydrops.

The question of timing

The remaining option — open fetal surgery to resect the intrapericardial tumor — has been attempted only a few times. One of those cases occurred during

Dr. Cass’s tenure as co-director of Texas Children’s Fetal Center, before his arrival at Cleveland Clinic. The fetus was in heart failure at the time of surgery; in addition to cardiac compression, the tumor’s shared vasculature with the heart reduced cardiac output. The heart surgeon was able to diminish the teratoma’s mass but could not completely excise the tumor. The fetus expired on the first postoperative day.

While acknowledging the complexity of that case, Dr. Cass believes initiating surgery earlier, before the onset of heart failure, would have improved the odds of survival.

The issue of surgical timing and fetal physiologic status also was emphasized in the CHOP team’s report of the single previous successful in utero intrapericardial teratoma resection. “A major contributor to our success was the ability to perform the fetal surgery prior to the onset of hydrops and thus avoid the development of a critically ill fetus,” the authors wrote of their resection, which was performed at 24 weeks’ gestation. The pre-hydrops interval was a “window of opportunity” to intervene.

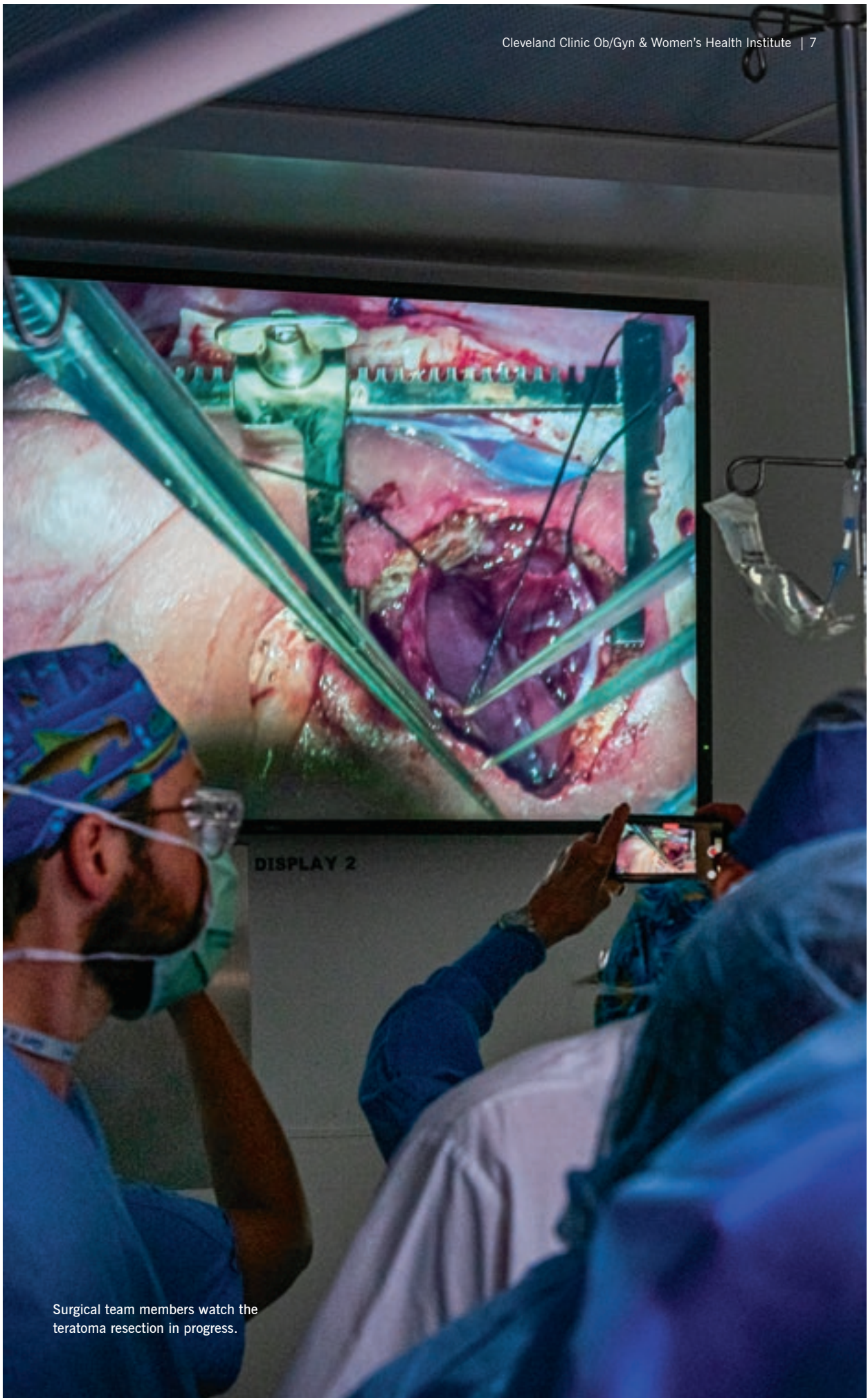By that criterion, the window of opportunity for Cleveland Clinic’s patient was already closed, since hydrops had developed and progressed since the mother’s admission.

Deciding to proceed

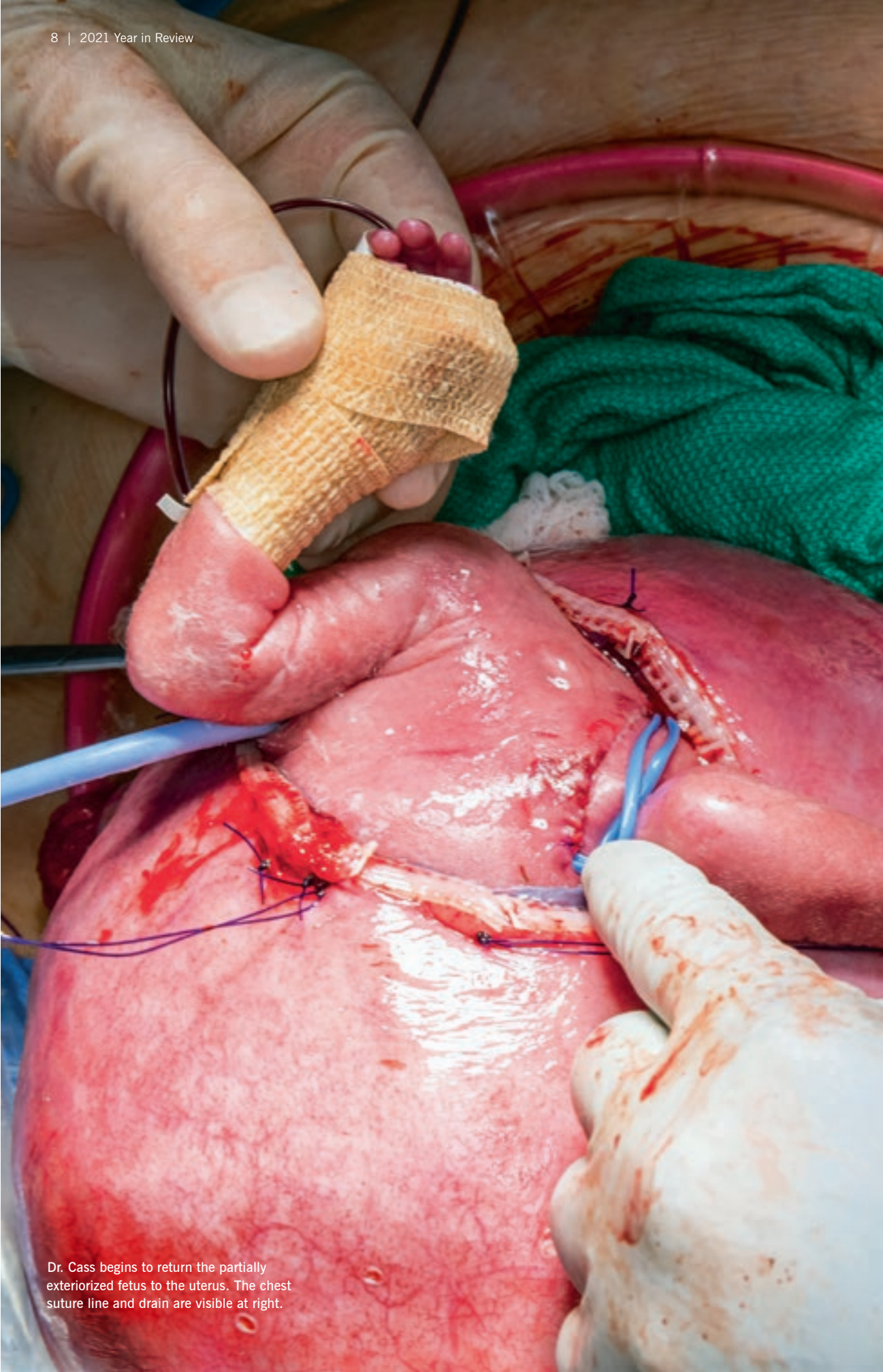The fetal care team met to review the medical literature, imaging and clinical status reports, and to discuss how to proceed. Moving forward with open fetal surgery required the assent of Dr. Cass along with representatives from pediatric cardiology, pediatric cardiac surgery and maternal-fetal medicine, as well as input from anesthesiology, labor and delivery nursing, and neonatology.

Dr. Najm had successfully resected intrapericardial teratomas in neonates several times but had never attempted the procedure in utero. A few non-Cleveland Clinic colleagues advised him not to operate, saying surgical mortality was almost certain.

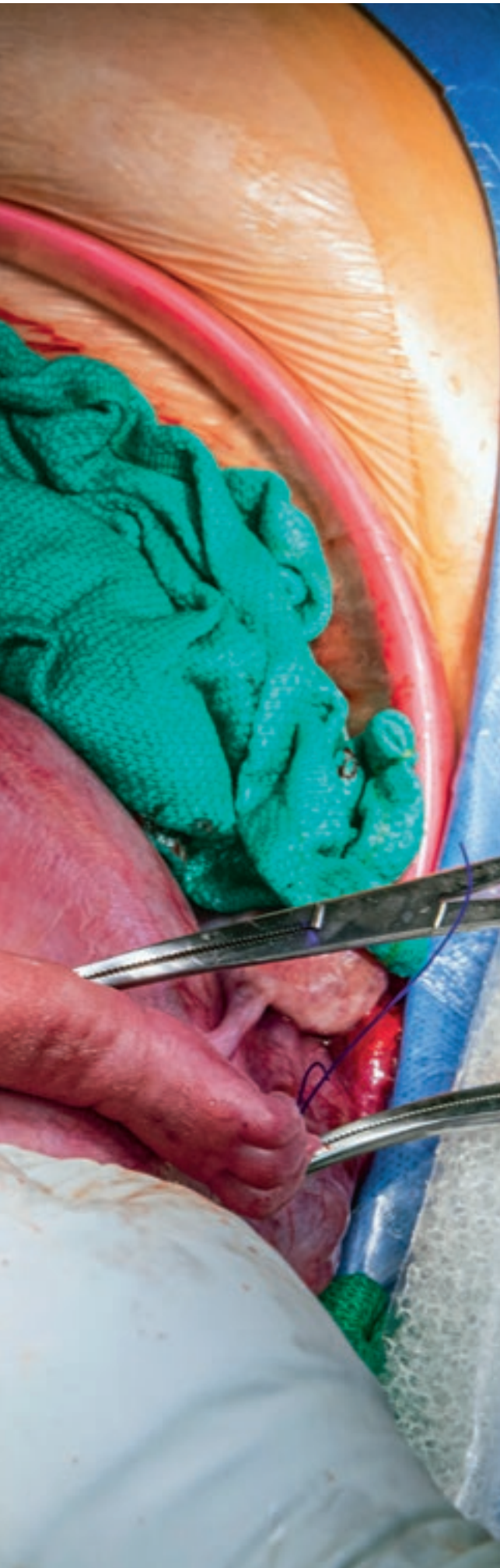(continued)



Surgical team members watch the teratoma resection in progress.



Dr. Cass begins to return the partially exteriorized fetus to the uterus. The chest suture line and drain are visible at right.



(continued)

“But based on my postnatal surgery experience,” Dr. Najm says, “if Drs. Cass and Kalan could safely get me access to the fetus’s chest, I knew that I could take out the tumor because the technical part is feasible. I felt very confident.”

“What you need is knowledge, teamwork and courage,” he says. “There is nothing wrong with a calculated risk. This is how we advance medicine.”

The other team members concurred.

“Dr. Najm is a great technical surgeon who has great outcomes, but he had not done fetal surgery before,” Dr. Cass says. “He put his trust in me and Dr. Kalan to take care of the mother and expose the baby” to enable resection of the tumor. “If we didn’t do something, the fetus was going to die. The family understood the risks and benefits and felt it was the right decision to proceed. So I had confidence that we would do the best we could.”

Developing backup plans

The fetal surgery team conducted a walkthrough of the procedure, reviewing participants’ roles and responsibilities and discussing the surgical plan.

Echocardiogram and fetal magnetic resonance imaging were not definitive on whether the tumor was merely attached to the heart’s surface or was invasive. Encountering the latter situation intraoperatively would require a modified approach.

“There was a possibility that the tumor was growing into the left atrium, and I was thinking about what I do if I have to cut part of the heart out,” says Dr. Najm, who is meticulous about having strategies to cope with unexpected complications. “Since the fetus would be on placental bypass, I may be able to put a vascular clamp or some sutures on the undersurface of the tumor where it is attached to the atrium and resect it with that part of the atrium.”

Alternately, if excising the entire teratoma appeared too dangerous due to the risk of hemorrhage or

(continued)

(continued)

impaired atrial function, “I could shave off most of the tumor and leave 1 or 2 millimeters,” Dr. Najm says. That would relieve the pericardial effusion and the cardiac disruption caused by the tumor’s bulk.

Subsequent postnatal operations could address remaining issues.

The operation unfolds

The surgery took place on the third day of admission, when the fetus was 26 weeks and 6 days old. The 30-year-old mother, who was gravida 2, para 1 and had gestational diabetes, was given an epidural and total intravenous anesthesia (TIVA), an approach favored by Drs. Hoyt and Hata to limit fetal exposure to inhalational agents.

“While inhalational anesthetics like sevoflurane relax the uterus nicely, they cause fetal cardiac depression,” Dr. Cass says. “So if you have a fetus where heart failure is a concern, an anesthetic agent that causes cardiac dysfunction is not a good situation. TIVA provides the safest environment to be successful with this tumor.”

Drs. Cass and Kalan made a relatively large transverse laparotomy incision to expose the uterus, then made an 11.5 centimeter incision through the uterine wall — large enough to exteriorize the fetus’s shoulders and arms and adequately expose the chest for the teratoma resection.

Because of the inability to directly attach monitoring lines to the fetus, Dr. Erenberg used intraoperative echocardiogram imaging to track fetal heart rate and contractility in real time. Dr. Najm inserted an IV line in a blood vessel of the fetus’s right arm to deliver anesthesia, fluids and medications as needed.

“We expected that we might have some changes in heart rate and blood flow as the surgeons worked in the pericardial space and tumor mass was removed, so the fetus might need some kind of support,” Dr. Erenberg says.

Indeed, as the surgeons manipulated the fetus in preparation for tumor resection, the heart rate fell, indicating distress. Using a bipolar cautery, Dr. Najm

quickly opened the chest and divided the sternum, which was cartilage, not bone, at that gestational stage. “Fetal tissue is immature and very delicate, so every movement has to be finessed, in slow motion,” he says. “We cannot use high cautery. We cannot lose any blood.”

When Dr. Najm opened the pericardium, draining its fluid, the fetal heart rate rebounded, aided by the IV infusion of saline and epinephrine.

The teratoma was the same size as the fetus’s heart. It was attached to the atrioventricular (AV) groove on the heart’s left side but did not appear to be invasive. Dr. Najm was able to create a smooth-looking plane between the AV groove and the tumor, which led him to believe he had been able to excise the entire mass.

With the pericardial depressurization and the removal of the tumor’s bulk, “the exciting thing was that the echocardiogram changed right as we were doing it,” Dr. Erenberg says. “Part of our worry was that the heart issues weren’t due to compression but represented a permanent problem, but the heart really sprang back to almost normal, right then and there.”

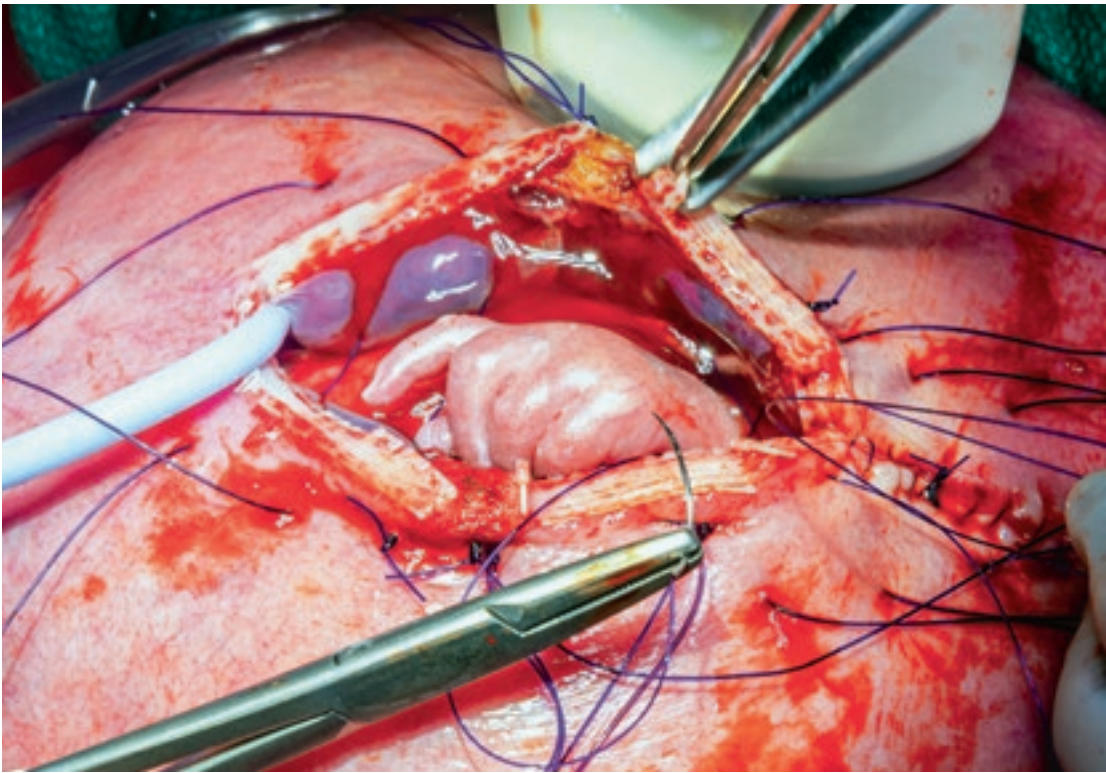
Dr. Najm cauterized a single feeding blood vessel, installed a drain and left the pericardium open to prevent fluid buildup, and sutured the sternum and chest skin.

Dr. Cass sutured the uterus and he and Dr. Kalan closed the mother’s abdomen. The surgery lasted 3.5 hours.

Outcome and prospects

The mother was subsequently discharged and her pregnancy continued normally for 10 weeks. She went into labor and the baby was delivered by cesarean section at 36 weeks, 2 days’ gestation. “Dr. Kalan took amazing care of the mother,” Dr. Cass says. “To extend the pregnancy by 10 weeks is a great achievement.”

The infant’s sternum did not properly heal, forming a fibrous union that will need to be surgically separated, repositioned and wired together in several months when calcification has increased.



The fetus's left hand is visible as the uterine incision is closed.

His mitral valve shows some mild abnormality and leakage, Dr. Erenberg says, a condition that may have become more pronounced after he developed iatrogenic respiratory syncytial virus pneumonia. “He will need to be monitored for a couple of years but has a good prognosis,” she says.

Histopathology examination revealed the intrapericardial mass to be a malignant germ cell tumor, a condition that also will require extended monitoring, particularly for elevated levels of alpha-fetoprotein. Postoperatively “we looked for evidence of tumor growth or recurrence and nothing happened,” Dr. Cass says. “And in the newborn period, the baby got CT scans of the chest and abdomen and there was no evidence of any tumor. So that is encouraging. It is very likely this infant is cured of his cancerous tumor.”

The successful fetal surgery outcome despite the presence of hydrops suggests to Dr. Cass that the more relevant determinant is the absence of heart failure. “Hydrops by itself can be tolerated,” he says. “It’s heart failure that we’re worried about. My theory is that it’s important to operate before the fetus has decompensated.”

Fetal surgery program's future

Next steps for Cleveland Clinic’s advancing fetal surgery program, according to Dr. Cass, are to begin offering a procedure called fetoscopic endoluminal tracheal occlusion to treat fetuses with severe pulmonary hypoplasia due to congenital diaphragmatic hernia, and to provide treatment for twin-twin transfusion syndrome.

Dr. Najm hopes to collaborate with Dr. Cass and Dr. Erenberg on other advanced fetal cardiac surgeries to address disrupted blood flow. “Vascular organs [like the heart] only develop if there is a flow to them,” Dr. Najm says. “If you have a valve that is closed, the chamber below it is not going to develop because that valve is atretic. But what if I can go in and open that valve, just puncture it? Would that ventricle grow? I believe it will. So if we believe in the flow theory, altering flows in utero will allow better development of different valves or chambers of the heart. I think this is the future.”

“I would like to take on harder and harder cases,” Dr. Cass says. “I’m proud of our team and teamwork.”

Prophylactic Tranexamic Acid May Prevent Hemorrhage Following Cesarean Delivery

TRAAP2 study results look promising, but more data are needed

The prophylactic use of tranexamic acid (TXA) may prevent hemorrhage following cesarean delivery, according to a recent study presented at the Society for Maternal-Fetal Medicine's (SMFM) 41st Annual Pregnancy Meeting.

"TXA has been studied extensively for its effectiveness in reducing the risk of bleeding in other surgical fields, such as trauma, orthopaedic and cardiac surgery," says Justin Lappen, MD, a maternal-fetal medicine specialist in Cleveland Clinic's Department of Obstetrics and Gynecology, who did not participate in the study. "We began using it a few years ago in obstetrics following the publication of the WOMAN trial in 2017. The thought was then that TXA could be used for prophylaxis; however, the TRAAP trial did not show a benefit, and therefore TXA was not used to prevent bleeding from vaginal delivery."

The World Maternal Antifibrinolytic (WOMAN) trial found a decrease in hemorrhage-related deaths in women given TXA after the onset of hemorrhage compared with a placebo, according to Dr. Lappen. In the Tranexamic Acid for the Prevention of Blood Loss after Vaginal Delivery (TRAAP) trial, women received TXA at the time of vaginal birth as a potentially preventive measure.

The TRAAP study found no statistically significant reduction in the risk of postpartum hemorrhage with prophylactic TXA, Dr. Lappen explains. "We know the risk of bleeding is greater with cesarean delivery compared with vaginal delivery. So, in the TRAAP2 trial, the team sought to determine if 1 g of TXA would prevent blood loss of > 1,000 mL or the need for transfusion by postpartum day two," he says.

TXA appears to reduce risk following cesarean

A total of 4,153 women were assessed for this primary outcome. There was about a 5% difference

between the TXA and placebo groups, which was statistically significant. Blood loss of > 1,000 mL or transfusion occurred in 556 of the 2,086 women (26.7%) in the TXA group, compared with 653 of the 2,067 women (31.6%) in the placebo group.


Dr. Lappen believes these results are interesting and looks forward to the results of a similar trial currently being conducted by the Maternal-Fetal Medicine Units Network (NCT03364491). Meta-analysis may also be helpful here, as outcomes such as transfusion or hysterectomy may be uncommon enough that we might not see enough of them in any one study. "It's possible that if we had more data, we may see more beneficial effects of TXA — not only in preventing strictly defined postpartum hemorrhage, but in preventing interventions required to treat hemorrhage or downstream adverse effects of hemorrhage, which can be quite meaningful to patients."

Giving new moms more time to bond with their neonates

"A transfusion or other procedures for postpartum hemorrhage can significantly affect a woman's health, recovery and experience of childbirth," Dr. Lappen explains. "Spending those first 24 hours with your baby — beginning to bond and breastfeed — these things can be meaningfully interrupted by a major hemorrhage. TXA is a safe and inexpensive medication that could reduce the risk of complications from postpartum hemorrhage."

Currently, patients at Cleveland Clinic receive TXA if they experience postpartum hemorrhage or excessive bleeding from surgery.





Intrauterine Vacuum Device Quickly and Safely Controls Postpartum Hemorrhage

Leveraging physiologic forces to achieve hemostasis

Quick and effective treatment

A new intrauterine vacuum device offers hope of preventing severe maternal morbidity and mortality by quickly and safely treating abnormal postpartum uterine bleeding or postpartum hemorrhage. Called the Jada® System, it was recently approved by the U.S. Food and Drug Administration based on results of a prospective, single-arm study at 12 medical centers in the United States.

“The success rate with the device in the clinical trial was 94% and it was effective in a median of three minutes,” says Edward Chien, MD, MBA, Chair of the Department of Obstetrics and Gynecology within Cleveland Clinic’s Ob/Gyn & Women’s Health Institute. “Only 5% of patients required use of a second or third intervention for continued bleeding, which is impressive compared with results of other uterotonic agents.”

The trial enrolled 107 women aged 18 years or older with normal uterine anatomy and placentation who delivered at ≥ 34 weeks’ gestation. Before use of the vacuum device, all had atony-related blood loss of 500-1,500 mL or 1,000-1,500 mL following vaginal or cesarean delivery, respectively. Blood loss criteria were developed acknowledging the American College of Obstetricians and Gynecologists’ revised definition.

The mean maternal age in the study was 29.7 years; 57% of the women were white and 24% were Black. Nearly two-thirds of the participants were obese. Eighty-five percent of the deliveries were vaginal.

The primary effectiveness endpoint was successful treatment of uterine atony, defined as no need for other open surgical or nonsurgical interventions after application of the Jada System. The primary safety

endpoint was incidence and severity of device-related adverse events (AEs), with data collected from enrollment to the 6-week follow-up visit.

“Failure to control bleeding occurred in only one case, and infection was reported in only 7% of cases,” says Dr. Chien, who co-authored the report on the study in *Obstetrics & Gynecology*.¹ “That issue was probably unrelated to the device itself because women with postpartum bleeding have higher rates of infection.”

The eight device- or procedure-related AEs in the study — none of which required treatment — were endometritis (N = 4), disruption of a vaginal laceration repair (N = 1), presumed endometritis (N = 1), bacterial vaginosis (N = 1) and vaginal candidiasis (N=1). There were no cases of uterine rupture, lower genital tract laceration or uterine incision dehiscence related to use of the Jada System.

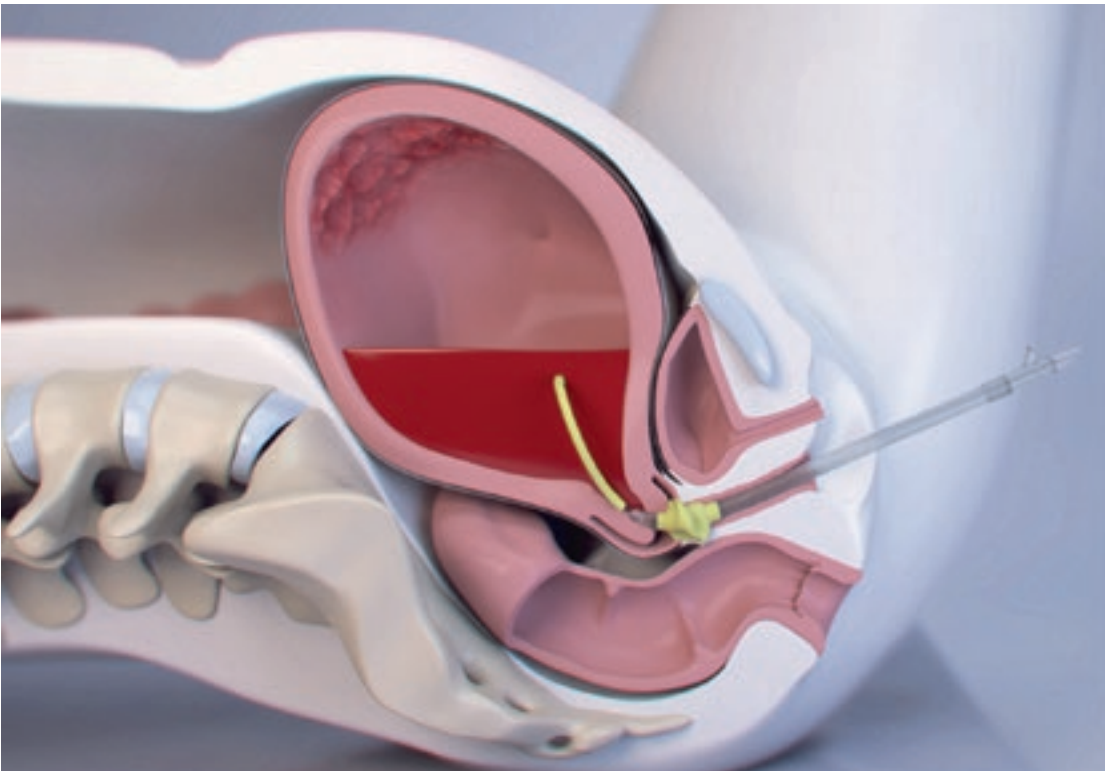
After use of the device, 35 participants required transfusion of one to three units of red blood cells (RBCs), and five participants required four or more units of RBCs.

About the device

Made of medical-grade silicon, the Jada System consists of an elliptical intrauterine loop on the distal end and a vacuum connector on the proximal end. Standard tubing is used to connect it with an inline graduated canister and regulated vacuum source. Twenty vacuum pores on the inner surface of the loop create a vacuum in the uterine cavity. On the outside, the pores are covered by a shield, protecting maternal tissue.

The device is introduced through the cervix into the uterine cavity, with the doughnut-shaped cervical

(continued)



The Jada System consists of an intrauterine loop and a vacuum connector. Standard tubing is used to connect it with an inline graduated canister and regulated vacuum source.

(continued)

seal just outside the external cervical os. The cervical seal is filled with 60-120 mL of sterile fluid, and a low-level vacuum (80 ± 10 mm Hg) is applied; the device is left in place with the vacuum on for at least one hour. Once bleeding is controlled, the vacuum is disconnected, the cervical seal emptied and the device left in place for at least another 30 minutes.

Says Dr. Chien, “The suction from the device causes the uterus to collapse. The muscle fibers then obstruct the arteries that are perforating the muscle to the lining of the uterus. That mimics the way postpartum blood flow is regulated, and it’s actually more physiologic than other intrauterine systems that inflate and potentially allow blood vessels to remain open.”

Some 98% of investigators in the trial said that the device was easy to use, and 97% would recommend it. Based on the positive data from the study and with the FDA approval, the Jada System is now being rolled out for use in Cleveland Clinic’s three major

maternity centers. Dr. Chien believes it can not only reduce maternal morbidity and mortality but also reduce costs associated with labor and delivery.

“This device is easy to use, and the response rate was impressive. Patients who responded were able to be transferred to normal postpartum units quickly instead of staying in labor and delivery for 24 hours,” he says.

“Our focus in maternal-fetal medicine is on patient safety and reducing pregnancy-associated morbidity and mortality, and this device should help us improve outcomes.”

Reference:

¹ D’Alton M, Rood K, Smid M, Simhan H, Skupski D, Subramaniam A, Gibson K, Rosen R, Clark S, Dudley D, Iqbal S, Paglia M, Duzyj C, Chien E, Gibbins K, Wine K, Bentum N, Kominiarek M, Tuuli M, Goffman D. Intrauterine Vacuum-Induced Hemorrhage-Control Device for Rapid Treatment of Postpartum Hemorrhage. *Obstet Gynecol*. 2020 Nov;136(5):882-891.

COVID-19 Vaccines and Fertility

The best time to get vaccinated is now for women who are or planning to become pregnant

As the COVID-19 pandemic continues, questions continue to arise about whether the vaccines pose risks to those who are pregnant or who are planning to have a baby. The Centers for Disease Control and Prevention (CDC recommends that everyone age 12 and older get the vaccine. Elliott Richards, MD, Director of Reproductive Endocrinology and Infertility Research at Cleveland Clinic, encourages healthcare providers to underscore the significant risks of contracting COVID-19, especially as highly transmissible variants emerge.

What does the most recent data tell us about the safety of the COVID-19 vaccines for pregnant women and those who are trying to become pregnant?

It is a common question in my practice: Is the vaccine safe for pregnancy and fertility? Many patients have questions and concerns about the vaccine and, in some cases, deep suspicions and fears. But I often will ask them to forget the vaccines for a moment. The better question is to ask: Is COVID-19 safe for pregnancy and fertility? And the answer is a resounding NO!

Even in overall healthy, young populations, COVID-19 can have long-lasting effects on one's lungs, brain, joints, GI tract and, yes, fertility. Pregnant patients with COVID-19 are at increased risk for severe complications, leading to ICU admission, intubation/ventilation and death. In addition, babies born to women who become infected with COVID-19 are more likely to be born premature, have lower birth weights, and experience severe complications including hypoxic-ischemic encephalopathy, blindness associated with prematurity, and intraventricular hemorrhage.

With the rise of super virulent forms of SARS-CoV-2, we are seeing increased hospital admission rates nationwide, even in populations such as young children, who we previously thought were relatively safe in the pandemic. Every discussion about COVID-19 and the vaccines should put the seriousness of this pandemic in context.

Realizing that COVID-19 poses a real threat to pregnancy and fertility, patients ask how they can protect their fertility and pregnancy from COVID-19.

The answer is, of course, *as many ways as you can.*

I have had patients discredit vaccines, masking and social distancing because one or some combination of these measures was not enough to prevent illness for them or a family member. It is perhaps tempting to label these in black-and-white terms as either wholly effective or ineffective. But they aren't either.

Each of these options confers varying levels of protection. A prior infection with COVID-19 provides some level of protection, but not absolute protection. That is why I recommend vaccination to all my fertility patients, and I recommend masking even to those who have been vaccinated.

To answer the original question: There was never any scientific basis — or even biologic plausibility — for the idea that the COVID-19 vaccines, including the mRNA vaccines, might cause problems with fertility or pregnancy.

Specifically, it is worth mentioning that neither the mRNA vaccines nor their byproducts have any relationship to syncytin-1, a critical component of syncytiotrophoblast development, which was at the heart of misinformation widely distributed on social

(continued)



Elliott Richards, MD, says the question that should be asked is not whether vaccines are safe for pregnancy and fertility but whether COVID-19 is. "The answer is a resounding NO!"



(continued)

media that the vaccines cause sterilization. Being composed of messenger RNA, these vaccines do not contain any virus particles, are not able to modify DNA and are only able to provide instructions for the body on how to make a portion of the SARS-CoV-2 glycoprotein.

Compared to other types of vaccines, an mRNA vaccine is a simple, elegant system with an extremely low likelihood of off-target effects. It is a triumph of modern medicine and engineering, and it is not hyperbole to assert that its development is one of the greatest achievements of humanity to date.

During the rollout of the vaccine over the past year, monitoring systems have consistently shown no safety concerns in pregnancy. Studies of semen parameters show no changes following vaccination. Now, with the release of the data from the v-safe pregnancy registry in early August 2021, we can be confident in the assertion that COVID-19 vaccines are safe in early pregnancy.

To put that in context: Earlier this year, many professional societies used somewhat vague language that the vaccine shouldn't be denied to pregnant patients. This month, the CDC has come out and explicitly stated that pregnant patients should receive the vaccine as soon as possible.

What are the timing considerations?

Earlier in the pandemic, I would often recommend that patients delay embryo transfer or pregnancy attempts until vaccination was completed (particularly the second dose of the mRNA vaccines) due to the concern that a febrile response to vaccination could theoretically affect early fetal development.

I worry now that some patients might take this advice to delay vaccination. The best time to get vaccinated is now. It doesn't matter where you are in your fertility journey, what fertility treatments you are contemplating or taking, get vaccinated now. There are no known downsides to the COVID-19 vaccine and plenty of downsides to the disease.

One of the concerns was about whether the vaccines could affect fertility in the future. Has this concern been shared by physicians as well?

I think it is telling that physicians are among the highest-vaccinated groups and that advocates for women's health have been some of the loudest voices in support of the vaccine. Given the mechanism of how they work, there is simply no reason whatsoever to suspect that vaccines will affect future fertility. On the other hand, there are many real concerns that COVID-19 can affect fertility in the future.

When the Time Comes: Developing a Complete View of the Risks of Research Studies of Human Germline Genome Editing

Ethical considerations must include the impact on those who would carry children with modified genomes

Experts in medical ethics, policy and genetic studies underscore the ethical implications of human experiments of human germline genome editing — the process of using molecular engineering to modify germ cells to effect changes that can be generationally inherited. While the process is banned in most countries, the existence of the technology demands that ethical considerations be made in advance.

In 2019, swift, negative reaction met the announcement that Chinese researcher He Jiankui had modified the *CCR5* gene in two embryos. Since then, no similar gene editing experiments are known to have been conducted, and it is unclear how the babies and their mothers have fared.

Members of the ethics and scientific communities have speculated about acceptable uses of clustered regularly interspaced short palindromic repeats (CRISPR) genome editing technology. To date, the health and well-being of children born after CRISPR genome editing have been the focus of debate about the use of this technology. While they are an important group to consider, they are not the only ones who may be affected by this research.

There has been little effort to examine the impact on study participants who may be willing to carry a genomically modified human embryo, but this important population must be apprised of the potential risks and benefits of such research.

A new commentary by Cleveland Clinic and Case Western Reserve University researchers provides perspective on the potential implications of a theoretical first-in-human clinical protocol for genomic modification of a human embryo. Published in *Accountability in Research*, the analysis is designed to serve as a resource for institutional review boards

(IRBs) that may be called on to assess the ethical and scientific frameworks of such research.

The need to consider women who carry children with modified genomes

“It occurred to us that the focus of discussion in the scientific, policy and ethics space has been on the children whose genomes were modified as embryos, without a lot of questioning about the risks to the woman who carried them,” says Ruth M. Farrell, MD, MA, Vice Chair of Research for the Ob/Gyn & Women’s Health Institute and first author of the piece.

Dr. Farrell and colleague Marsha Michie, PhD, assistant professor in the Department of Bioethics at Case Western Reserve University, have received a three-year, \$1.77 million National Institutes of Health grant to further examine the topic.

“We see our commentary serving in a proactive role, bringing attention to pregnant persons in studies of human genomic modification. That way, we can help prepare scientists, policymakers and IRBs for the challenges that will come if and when this research moves forward,” Dr. Farrell says. “Our work is not an endorsement of human genome editing, nor is it in preparation for any such experiments. It is a way to draw attention forward to what science can accomplish and what we should have in place in conjunction with those advances. We want to be anticipatory and encourage thought leaders, scientists, clinicians and policymakers to consider what safeguards should be in place.”

The authors underscore the importance of including pregnant persons and families as stakeholders in use of genomic technology and express concern about

(continued)



(continued)

potential harm to them if research moves forward too rapidly. They view IRBs as holding one of the keys to creating a research path that is ethically and scientifically responsible.

“Our IRBs play a key role in ensuring protections of human subjects who may participate in trials of human genome editing,” Dr. Farrell says. “Yet, they are not the only resource to ensure that safeguards are in place. It is also funding and research organizations and policymakers.

Recommendations

The researchers plan to add their recommendations for IRBs in the context of the theoretical cases for use of germline editing put forth previously by the National Academies of Sciences, Engineering, and Medicine. Those recommendations include what risks should be considered for the pregnant person and offspring. While the focus of protections is often the informed consent process, the outcomes, serious adverse events and other methodological considerations also affect risks to which study participants may be exposed.

Were an IRB to review such a protocol, considerations must include the risks to the maternal-fetal dyad during pregnancy.

“When we think about studies that involve human embryo modification, we have to include in the discussion not just the offspring born from these studies, but also the women who will become pregnant with these embryos and their families,” says Dr. Farrell. “Their interests need to be prioritized because we have an ethical obligation to minimize risk for all study participants.”

The authors recommend that IRBs take a broad view of human genome editing. They suggest that panels reviewing future protocols include experts in behavioral research, reproductive health and human genome editing as well as select members of the public so that psychological, relational and social implications of the technology can be explored.

AI Tool Shows that Blastocyst Pumping Can Predict Implantation Failure

Study reveals another ranking criterion that may aid in embryo selection

A team of researchers using computer vision analysis of time-lapse videos of embryos ascertained that blastocyst pumping events have a high negative predictive value for subsequent failed implantation. Results of the study, led by Israel-based AiVF, were presented at the American Society for Reproductive Medicine's 2021 Scientific Congress & Expo.¹

“The purpose of the study was to use artificial intelligence (AI) to deselect embryos that are less likely to implant,” says Nina Desai, PhD, HCLD, Director of Cleveland Clinic's In Vitro Fertilization Lab and study co-author. “When we have five or six blastocysts, we use different criteria to rank them and give patients the best opportunity to get pregnant on their first or second transfer.”

Cleveland Clinic's IVF Lab is one of a few clinics in the country that performs time-lapse (TL) cultures of all patient embryos. The lab has five EmbryoScope® TL chambers that provide continuous imaging data on embryos.

Study methods

During development, the blastocyst pushes against the surrounding zona pellucida to expand. “Some embryos do this beautifully, while others struggle and go through a series of contractions and expansions, which you can see using time-lapse videos,” says Dr. Desai.

Using AiVF's AI-based digital embryology management platform, the researchers studied



these contractions and expansions to see whether blastocoelic contractions greater than 8 microns in diameter were associated with poor implantation rates independent of other morphokinetic features.

The team analyzed 148,441 images from TL sequences of 317 expanded blastocysts chosen for transfer with known implantation data. It used the following definitions:

- A “pumping event” or “weak contraction” occurs when the diameter of the blastocyst is more than 8 microns smaller than it was 40 minutes earlier.
- A contraction in blastocyst diameter greater than 16 microns is a “major pumping event.”
- A contraction greater than 8 microns but no more than 16 microns is a “minor pumping event.”
- An “early pumping event” occurs when the blastocyst is up to 140 microns in diameter.
- A “late pumping event” occurs when the blastocyst is more than 140 microns in diameter.

Researchers measured the number and extent of pumping events, as well as the stage of blastulation at which they occurred, and compared them to the known implantation outcomes of the embryos.

Research results

“We found differences in the number of weak contractions between embryos that implanted and those that did not implant,” says Dr. Desai. “We also found significant differences in major pumping events of more than 16 microns. The odds ratio (OR) was 1.8-fold higher for not implanting if the blastocyst showed a major pumping event.”

Of the 317 blastocysts studied, 188 (59.3%) successfully implanted. Among those, early pumping was noted in 27 (14%) blastocysts, while early pumping occurred in 22 (17%) of the 129 blastocysts that failed to implant. Major pumping events occurred in 14 (7%) blastocysts that implanted compared to 18 (14%) blastocysts that failed to implant. Major pumping events were significantly correlated with implantation failure (OR 1.87, *P* = 0.03 for at least one major pumping event and OR 2.42, *P* = 0.04 for at least two major pumping events).

Clinical implications

This study indicates that blastocyst pumping events can be used as one criterion to rank and deselect certain embryos, says Dr. Desai.

“The next step in the world of IVF is to harness the power of AI to identify the embryo you want to transfer because of subtle features that give you a clue as to what’s happening inside of it,” she says. Ultimately, this benefits patients.

“IVF is very expensive, and we want patients to get pregnant in the first two cycles,” says Dr. Desai. “Being able to eliminate embryos that are less likely to implant shortens the time to pregnancy.”

Reference:

¹ Gilboa D, Seidman D, Kedar L, Maor R, Kottel I, Goldberg J, Falcone T, Desai N. Blastocyst “pumping” is a detrimental feature predicting implantation failure: highly accurate assessment by computer vision analysis of time-lapse videos. 2021 Oct. Retrieved from <https://asrm.confex.com/asrm/2021/meetingapp.cgi/Paper/12529>.

Laparoscopic Resection of Cesarean Scar Ectopic Pregnancy

A case study of this rare presentation

By Cara King, DO, MS

Presentation

A 29-year-old woman presented to the emergency room with symptoms of abdominal pain and vaginal bleeding. Ultrasound confirmed a 9+5 week pregnancy located within the lower uterine segment with crown rump length measuring 22 mm, which extended into a previous cesarean section scar. The lower uterine segment was ballooned anteriorly abutting the bladder without an obvious plane. She had had six previous pregnancies, including four previous cesarean section deliveries, and had a strong desire for uterine preservation. Other relevant medical history included tricuspid valve replacement in 2016. Physical exam revealed a 10-week uterus, mildly tender to palpation, and speculum examination

revealed a closed cervix with scant red-brown blood. Her blood pressure and pulse were within normal limits; her hCG (human chorionic gonadotropin) level was 53,654 mIU/mL.

A definitive diagnosis of cesarean scar ectopic pregnancy (CSEP) was made, and the patient was admitted for uterine artery embolization and ultrasound-guided intragestational sac methotrexate injection to decrease the blood flow to the ectopic pregnancy. She was followed with serial ultrasounds and beta hCGs, which trended down to 58.6 mIU/mL. She was ultimately scheduled for laparoscopic resection of the CSEP, isthmocele resection and repair, and lysis of adhesions.

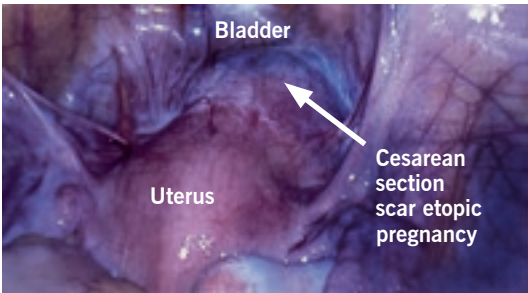
The procedure

To help with hemostasis, a dilute vasopressin solution was injected transvaginally into the cervical stroma as well as laparoscopically around the isthmocele. We noted that the gestational sac contained a fetus at 9 weeks. We excised the remaining isthmocele, inserted a RUMI® manipulator and performed a gentle curettage through suprapubic port to ensure all products of conception were removed. We then closed the myometrium. After ensuring watertight closure, we placed the isthmocele tissue in an endocatch bag and removed it through the umbilicus without difficulty.

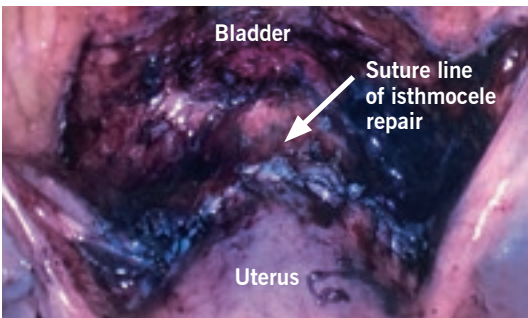
We extubated the patient and transferred her to the PACU in stable condition. The patient was discharged home the same day.

Diagnosis requires high index of suspicion

CSEP — defined as the implantation of a blastocyst within a previous cesarean scar — is rare, occurring in approximately 1 in 2,000 pregnancies. CSEP accounts for only about 6% of all ectopic pregnancies in patients who have had previous cesarean sections.



Laparoscopic image revealing a cesarean section scar ectopic pregnancy at 9+5 weeks gestation.



Laparoscopic image status post laparoscopic removal of cesarean section scar ectopic pregnancy and isthmocele repair.

Before implanting, it is thought that the embryo may migrate through a defect in the lower uterine segment or a microscopic fistula in the scar. Patients may present with abdominal cramps, low abdominal pain or vaginal bleeding, or they may be asymptomatic and present for evaluation for ectopic pregnancy. If undetected, CSEP can lead to uterine rupture or hemorrhage. Diagnosis is made via ultrasound and often requires a high index of suspicion. Medical treatment may take months and carries the risk of uterine rupture and life-threatening hemorrhage. Laparoscopic resection, in this particular case, removed the products of conception and allowed for repair of the defect with uterine preservation.





Antibiotics Prior to Immunotherapy Associated With Decreased Survival in Recurrent Gynecologic Cancers

Study finds 10-month survival difference

Antibiotic therapy 30 days before the initiation of immunotherapy is associated with reduced response rate, progression-free survival and overall survival in women with recurrent gynecologic cancers, according to a recent study from Cleveland Clinic.

“Understanding factors that may contribute to immunotherapy resistance is essential to improving survival for our patients,” says Laura Chambers, DO, first author on the study.

“Studies in patients with nongynecologic cancers, such as melanoma and non-small cell lung carcinomas, have demonstrated that antibiotics prior to immunotherapy may negatively affect treatment outcomes,” she adds. We sought to understand how this would impact women with gynecologic cancer.”

More than half of patients received antibiotics

In a retrospective study recently published in *Gynecologic Oncology*,¹ Dr. Chambers and Roberto Vargas, MD, clinical assistant professor at the Cleveland Clinic Lerner College of Medicine and Case Western Reserve University, and associate staff in Gynecologic Oncology at Cleveland Clinic, looked at 101 women with recurrent endometrial cancer, cervical cancer or ovarian cancer who received immunotherapy between January 2017 and September 2020.

Of that group, 58 women (56.9%) received antibiotics, with 23 (22.8%) receiving antibiotics within the 30 days before immunotherapy treatment and 47 (46.5%) receiving antibiotics concurrently.

Patients received antibiotic treatment for a variety of reasons. There were no differences in indications for antibiotics between the groups.

A significant survival difference

Researchers found that antibiotics prior to immunotherapy were associated with a significant reduction in progression-free and overall survival in women with endometrial, cervical and ovarian cancer. Furthermore, antibiotics prior to immunotherapy were also associated with a significantly decreased immunotherapy response, compared with patients who did not receive antibiotics or only received them during their immunotherapy.

Patients who received antibiotics within 30 days of immunotherapy had a shorter progression-free survival of 2.9 months, compared with those who had concurrent antibiotics or no antibiotics, with progression-free survival of 8.9 months. Those who had antibiotics prior to immunotherapy lived 9.3 months compared with 19.9 months for those who had concurrent antibiotics and no antibiotics.

“Further prospective study is needed to understand the mechanism through which the timing of antibiotic therapy impacts outcomes, particularly the impact on the gut and intratumoral microbiome,” says Dr. Vargas.

Previous research has demonstrated that antibiotic treatment is a negative predictor of response to immunotherapy and overall survival in patients with melanoma, non-small cell lung cancer, bladder cancer and renal cell carcinoma. Its effects on response rates, progression and outcomes in patients with gynecologic cancer had not been elucidated until now. Studies in nongynecologic cancers have demonstrated the gut microbiome is one mechanism through which antibiotics may impact oncologic outcomes.

Reference:

¹ Chambers L, Michener C, Rose P, Reizes O, Yao M, Vargas R. Impact of antibiotic treatment on immunotherapy response in women with recurrent gynecologic cancer. *J. Gynecol. Oncol.* 2021 Apr;161(1):211-220. DOI: 10.1016.

Endometrial Sampling Has a Role in Detecting Leiomyosarcoma

Study identifies factors that improve preoperative detection and procedures

A recent study of the effectiveness of endometrial sampling in detecting leiomyosarcoma (LMS), an aggressive uterine cancer with a poor prognosis, indicates that when sampling is done in conjunction with hysteroscopy before hysterectomy, there is a threefold increase in preoperative diagnosis.

Rosanne M. Kho, MD, of Cleveland Clinic's Ob/Gyn & Women's Health Institute, was lead author on the research published in the *Journal of Minimally Invasive Gynecology*.¹

Rethinking the utility of endometrial sampling

Symptoms of leiomyosarcoma often mimic uterine leiomyomas, which can include abnormal bleeding, pelvic pain and infertility. While LMS is rare, occurring in only 13 out of 10,000 surgeries for presumed leiomyomas, the prognosis for LMS patients is poor. The five-year survival rate for disease diagnosed at stage I is 55.4%; at stage IV it is 13.1%.

Pre-surgical diagnosis is notably difficult. Postmenopausal and Black women are at higher risk, as are those with a history of pelvic radiation or extended use of tamoxifen, and those who present with a single, rapidly growing tumor with atypical features. No diagnostic test exists to reliably differentiate LMS tumors from a benign fibroid.

"We are continually trying to find ways to catch these patients before we go in with surgery," Dr. Kho says. "In many situations of leiomyosarcoma, surgery should not be the first approach. If surgery is to be performed, you need to be ready with the right team. It has to be in the hands of the oncologists."

The researchers examined linked data from the New York Statewide Planning and Research Cooperative System and the New York State Cancer Registry from 2003 to 2015. The study subjects were women with uterine leiomyosarcoma who had undergone

endometrial sampling within 90 days before a hysterectomy. Among 79 cases that met the sampling criteria, 46 received a preoperative diagnosis of LMS and 33 had been diagnosed postoperatively.

Leiomyosarcoma was picked up by endometrial sampling about 58% of the time.

"Historically, it was thought that these cancers were contained only within the myometrium and that, therefore, an endometrial sampling would not be very helpful, because you're not sampling the tumor itself," says Dr. Kho. "To find that 58% of the time the result is positive suggests that it's worthwhile."

In addition, the study found that the detection rate tripled for cases in which hysteroscopy was used during sampling procedures — pipelle biopsy or dilation and curettage.

"The assumption is that when you use hysteroscopy, you can better direct where to sample," Dr. Kho says. "Hysteroscopy at the time of sampling should be the gold standard. It has been declared as a gold standard for over 10 years, yet it still is not routinely done. There's a role for preoperative sampling, and if preoperative sampling is to be done, consider using hysteroscopy rather than performing a blind sampling alone."

The researchers also found that in some women whose LMS was not detected before surgery, the chosen procedure was supracervical hysterectomy. "We know that you don't do that in cancer surgery," Dr. Kho says.

In general, she adds, the advantages of supracervical hysterectomy have been shown to be minimal.

"There is strong evidence from the Cochrane Review that it really does not confer any advantage other than the fact that you do not subject the patient to a


vaginal cuff dehiscence,” says Dr. Kho. “There are no benefits in terms of bladder, bowel or sexual function in leaving the cervix behind. It used to be thought that if you leave the cervix behind, there’s better sexual function or there is less risk of a prolapse or fewer complications, but that did not bear out as true.”

The endometrial sampling study did not find that the prognosis or the survival rate was worse in women whose diagnoses were missed. Dr. Kho attributes that to possibly the limited sample size in the retrospective research. A prospective study that gathers data from medical centers across the country will be needed, she says.

Reference:

¹ Kho R, Desai V, Schwartz P, Wright J, Gross C, Hutchison L, Boscoe F, Lin H, Xu X. Endometrial sampling for preoperative diagnosis of uterine leiomyosarcoma. *J Minim Invasive Gyneco*. DOI. Retrieved from <https://doi.org/10.1016/j.jmig.2021.07.004>.





Vaginal Insert Offers Relief from Fecal Incontinence

Device provides alternative to conservative management and surgical procedures

More than 1 in 10 adult women in a population-based study indicated they have fecal incontinence, with 1 in 15 experiencing moderate to severe symptoms. Yet the condition often goes untreated.

“It’s a bigger problem than most people realize,” says Shannon Wallace, MD, a physician in the Division of Urogynecology and Pelvic Floor Disorders at the Ob/Gyn & Women’s Health Institute. “Not many primary care physicians or gynecologists really ask about fecal incontinence, and patients don’t bring it up because it’s embarrassing and uncomfortable.”

Until just a few years ago, patients who broached the topic with physicians had two primary treatment paths — conservative management or surgical procedures. In 2015, Pelvalon introduced the Eclipse™ System, the first vaginal insert designed to provide bowel control. (Laborie Medical Technologies Corp. acquired Pelvalon in October 2021.)

“Patients didn’t have many options between doing pelvic floor physical therapy and making dietary changes or ending up with some surgical procedure. The benefit of the Eclipse is that it targets the middle market,” says Dr. Wallace, who fitted more than a dozen patients with the device during her Female Pelvic Medicine and Reconstructive Surgery Fellowship at Stanford University Hospital.

How the device works

The Eclipse System features a vaginal insert, tubing and detachable inflation pump. The insert is a dual-layer balloon with a silicone surface and a polyurethane bladder that’s held in place with a

flexible base made of silicone and stainless steel. A tube, which is connected to a pressure sensor, descends out of the vagina and attaches to the pump. When inflated, the pump presses on the rectum to prevent fecal incontinence. The patient squeezes the pump three times to deflate the balloon and have a bowel movement. The pump can then be reinflated.

“It is similar to a vaginal pessary for prolapse,” says Dr. Wallace. Contracted urogynecologists and colorectal surgeons customize the pressure, balloon and base size to each patient, who receive a trial device for a few weeks to ensure the right fit. Once they receive their personal device, patients can insert it themselves and take it out routinely to clean it or opt for their physician to do so during office visits.

In a pivotal study of the system, women who had a minimum of four fecal episodes over two weeks were fitted with the device. The success rate at three months was 86.4%.

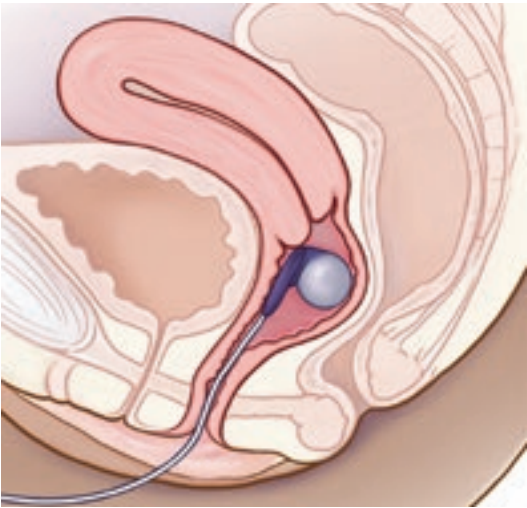
Evaluating patients with fecal incontinence

Like any treatment option, the vaginal insert is not indicated for all patients with fecal incontinence. Common causes of anal incontinence include obstetric trauma, surgical trauma and pelvic floor denervation. Dr. Wallace notes that an evaluation of fecal incontinence is key to determining the best treatment and recommends this step-by-step approach:

Conduct an initial clinical assessment, including a patient history and physical, a medical and diet review, an assessment of quality of life, and a colonoscopy. During the physical examination, look for rectal prolapse, hemorrhoids, skin tags, sphincter tears and paradoxical muscle contraction.

Address any reversible factors, such as medicine side effects, diet and diarrhea.

Consider specialized assessments, including a comprehensive anorectal exam and pelvic floor physiology testing (anal manometry and electromyography, endoanal ultrasound and defecography). Other tests may include flexible sigmoidoscopy in patients under 40 to exclude



After being inserted into the vagina and inflated, the Eclipse pump prevents fecal incontinence by pressing on the rectum.

mucosal inflammation or masses and stool studies in patients with chronic diarrhea.

“If your patient reports fecal incontinence, it warrants a consultation with a colorectal surgeon or urogynecologist to have an appropriate workup,” says Dr. Wallace. “Once that workup is done and they have tried conservative therapy, then the Eclipse is a reasonable option to avoid surgery.” She adds that patients with no prolapse and normal to high sphincter strength and whose symptoms affect their quality of life are good candidates for Eclipse.

A paradigm shift

Today, there are several options for treating fecal incontinence, from conservative management to the vaginal balloon insert and surgeries, such as sphincteroplasty, end-to-end anastomosis and sacral neuromodulation. It’s incumbent on primary care physicians and gynecologists to guide patients toward a solution.

“As women get older, they are told that urinary and fecal incontinence are part of life. But I think there’s been a paradigm shift happening in the past decade or so,” says Dr. Wallace. “Physicians should ask their patients about incontinence and advocate for the best treatment options.”

Pain in Transgender Men Undergoing Hysterectomy

Study finds lower incidence of endometriosis than in cisgender patients

Less than one-quarter of transgender men undergo hysterectomy for gender affirmation, and few reports exist about outcomes of the surgery. Studies have been done of uterine pathology in this population, but no literature has been published about intraoperative findings from patients undergoing female-to-male gender affirmation.

A new study¹ by researchers from Cleveland Clinic and MetroHealth Hospital aims to help fill that gap by exploring preoperative pain and incidence of endometriosis at hysterectomy, in transgender men. Interestingly, half the patients reported pelvic pain before hysterectomy but the incidence of endometriosis found during surgery was much lower than what is typically seen in the cisgender population seeking hysterectomy for pain.

“The clinical implication is that while a large number of transgender men have pelvic pain, many do not have endometriosis,” says Cecile Ferrando, MD, Director of Transgender Surgical Services at Cleveland Clinic. “However, pelvic surgeons should not be surprised to find endometriosis in transgender men seeking hysterectomy, even if they report amenorrhea on testosterone therapy.”

Study at a glance

Data for the research were from a retrospective chart review of transgender men presenting for gender-affirming hysterectomy between 2010 and 2019. All the surgeries were minimally invasive and done under general anesthesia by two surgeons highly experienced in caring for transgender patients.

A total of 67 transgender men (men who were designated female at birth) were included. The mean age was 29 years, and the mean body mass index was 28.6. Sixty of the patients (89.5%) had used testosterone for gender-affirming hormone therapy for a mean of 36 months (range, 12-300).

Of the hysterectomies, 66 (98.5%) were total laparoscopic with salpingo-oophorectomy and one was total laparoscopic with ovarian preservation.

Prior to surgery, 34 of the patients (50.7%) reported pelvic pain at any time since menarche, which was constant in 35.3% and cyclic in 64.7%. Overall, endometriosis was diagnosed intraoperatively in 18 of the patients (26.9%). It was seen in 32.3% of those with and 21.9% of those without pelvic pain.

Of the cases of endometriosis, 70% were either stage I or II, and stage was not associated with preoperative pain symptoms.

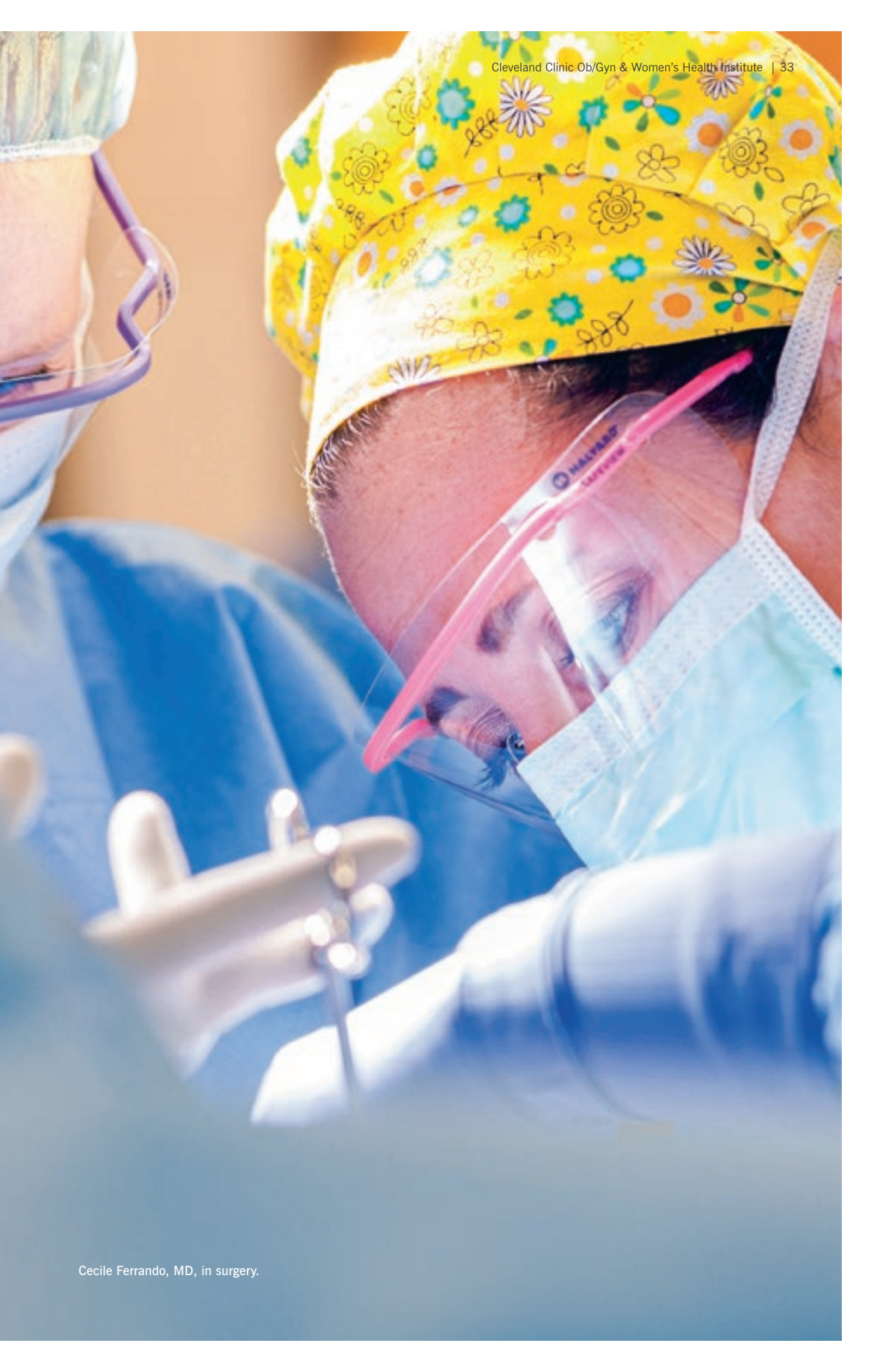“Pain is probably a multifactorial thing in this patient population,” says Dr. Ferrando. “There may be a component of the pain that is associated with experiencing gender dysphoria, and it’s also hard to know how transgender men cope with what some cisgender women would consider normal pelvic cramping or discomfort at the time of menses.”

The researchers found that testosterone was not associated with the presence of endometriosis, preoperative pain or irregular bleeding.

“The pelvic organs are usually smaller in transgender men who are on testosterone, and there is a presumption that, therefore, hysterectomy will be straightforward,” says Dr. Ferrando. “But surgeons should be prepared to find endometriosis in these patients and to deal with it, which makes the procedure more complicated.”

Reference:

¹ Ferrando C, Chapman G, Pollard R. Preoperative pain symptoms and the incidence of endometriosis in transgender men undergoing hysterectomy for gender affirmation. *J Minim Invasive Gyneco*. 2021 Sep;28(9):1579-1584.



Cecile Ferrando, MD, in surgery.

Ob/Gyn & Women's Health Institute

At a Glance

13 centers across the region and in Florida

- Endometriosis and Chronic Pelvic Pain
- Fertility
- General Gynecology
- Gynecologic Infectious Diseases
- Gynecologic Oncology
- Maternal-Fetal Medicine
- Menstrual Disorders, Fibroids and Hysteroscopic Services
- Minimally Invasive Gynecologic Surgery
- Obstetrics and Family Maternity Center
- Postpartum Care Clinic
- Pregnancy and Cancer
- Specialized Women's Health
- Urogynecology and Pelvic Floor Disorders

Shared medical appointments

The Ob/Gyn & Women's Health Institute offers shared medical appointments in these centers:

- General Gynecology
- Obstetrics and Family Medicine
- General Obstetrics and Gynecology, Florida
- Menstrual Disorders, Fibroids and Hysteroscopic Services
- Specialized Women's Health
- Urogynecology and Pelvic Floor Disorders

Virtual visits

Virtual visits allow patients to communicate in real time (audio and video) with their providers from their home, office or elsewhere via a computer or smartphone.

Clinical research by the numbers

- \$2.9 million in new research funding
- 249 studies
- 165 publications

Patient activity

Hospital admissions	11,299
Surgical procedures performed*	9,677
Deliveries	9,974
Outpatient visits	415,187
Shared medical appointments	302
Virtual visits	40,031

Caregivers

Ob/Gyns	162
Certified nurse midwives	29
Advanced practice nurses	51
Residents	27
Fellows	18

*Excludes cesarean sections

Statistics reported are from July 1, 2020, to June 30, 2021.



Resources for Physicians

Consult QD — Ob/Gyn & Women's Health

News, research and perspectives from Cleveland Clinic experts:
consultqd.clevelandclinic.org/obgyn

Ob/Gyn ePerspectives

To subscribe, visit:
clevelandclinic.org/obgynnews

24/7 Referrals

855.REFER.123
clevelandclinic.org/refer123


Outcomes Data


clevelandclinic.org/outcomes


CME Opportunities


Visit ccfcme.org for offerings from Cleveland Clinic's Center for Continuing Education.

Connect with us

 [Facebook.com/CMEClevelandClinic](https://www.facebook.com/CMEClevelandClinic)

 [@CleClinicMD](https://twitter.com/CleClinicMD)

 clevelandclinic.org/MDlinkedln

 clevelandclinic.org/obgyn

Ob/Gyn & Women's Health Institute 2021 Year in Review

Managing Editor
Karen Sandstrom

Art Director
Joanne Kilbane

Assistant Art Director
Bernastine Buchanan

Photography
Marty Carrick, Lisa DeJong, Don Gerda,
Shawn Green, Annie O'Neill

Illustration
Martha Liechty

Marketing
Erin Radigan

The Ob/Gyn & Women's Health Institute's *2021 Year in Review* is written for physicians and should be relied on for medical education purposes only. It does not provide a complete overview of the topics covered and should not replace the independent judgment of a physician about the appropriateness or risks of a procedure for a given patient.



Every life deserves world class care.

9500 Euclid Ave., Cleveland, OH 44195

Cleveland Clinic is a nonprofit, multispecialty academic medical center integrating outpatient and hospital care with research and education for better patient outcomes and experience. More than 4,500 staff physicians and researchers provide services through 20 patient-centered institutes. Cleveland Clinic is a 6,026-bed healthcare system with a main campus in Cleveland, 18 hospitals and over 220 outpatient locations. The health system includes five hospitals in Southeast Florida with more than 1,000 beds, a medical center for brain health in Las Vegas, a sports and executive health center in Toronto and a 364-bed hospital in Abu Dhabi. Cleveland Clinic London, a 184-bed hospital, will open in 2022. Cleveland Clinic is currently ranked as one of the nation's top hospitals by *U.S. News & World Report*.
clevelandclinic.org

©2021 The Cleveland Clinic Foundation



The Cleveland Clinic Foundation
9500 Euclid Ave. / AC311
Cleveland, OH 44195